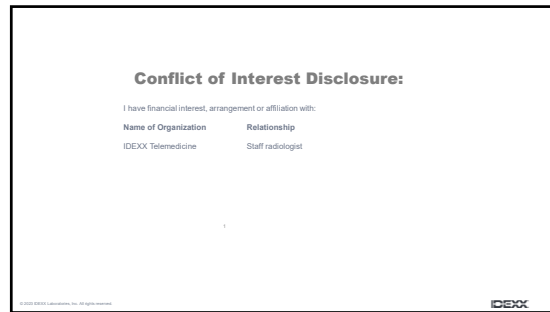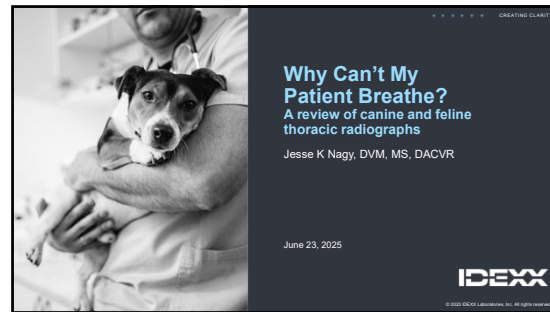



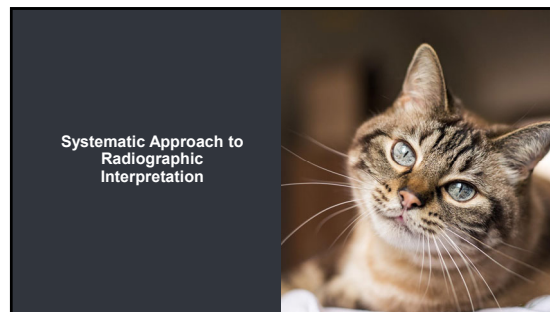
1



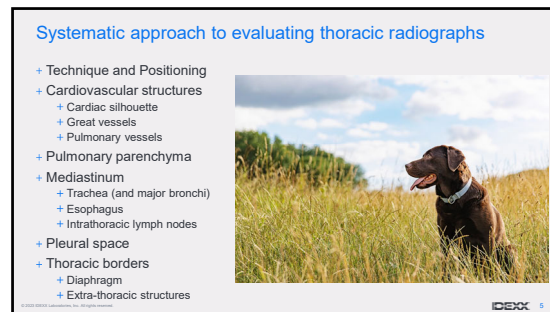
2



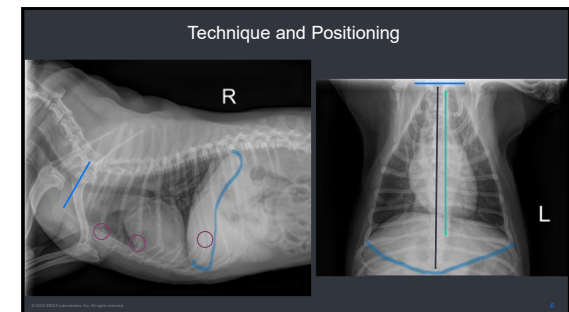
3



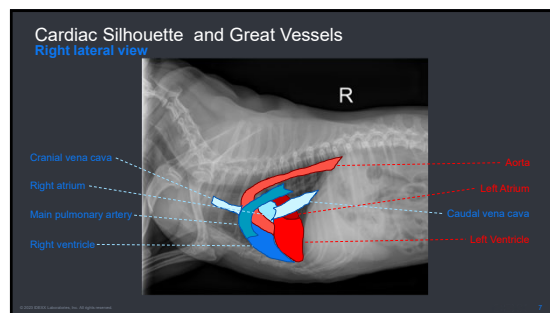
4



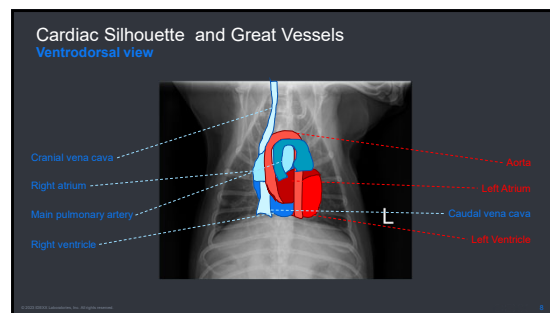
5



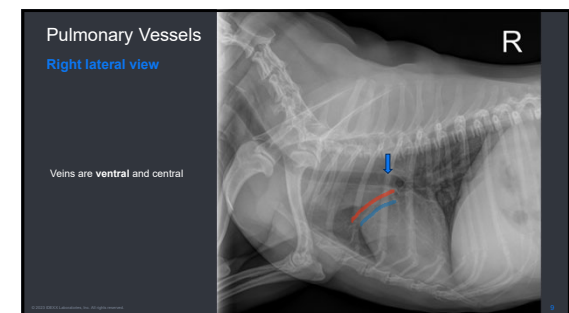
6



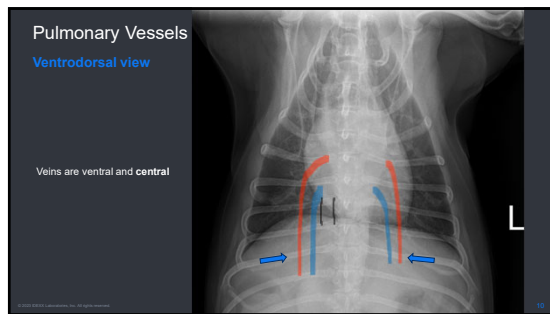
7



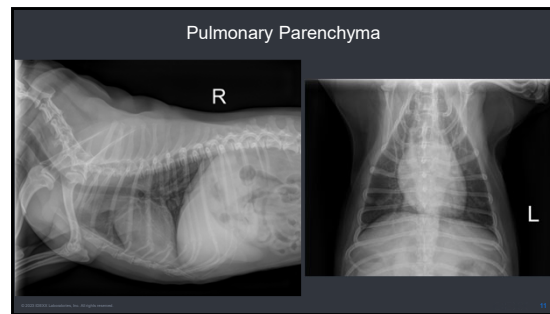
8



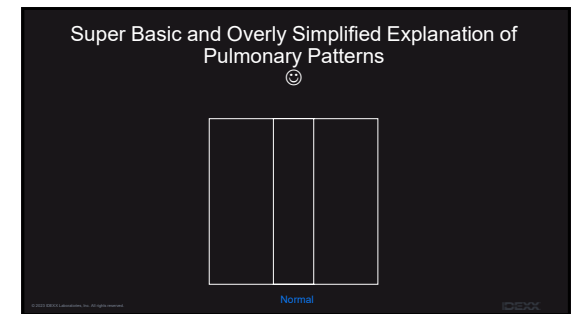
9



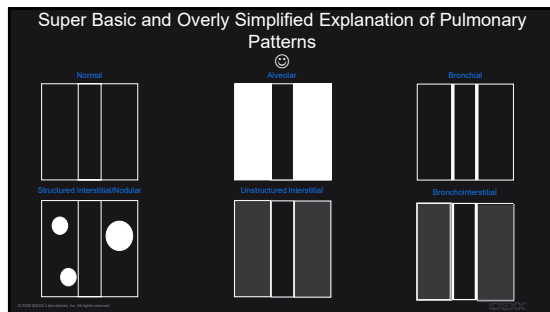
10



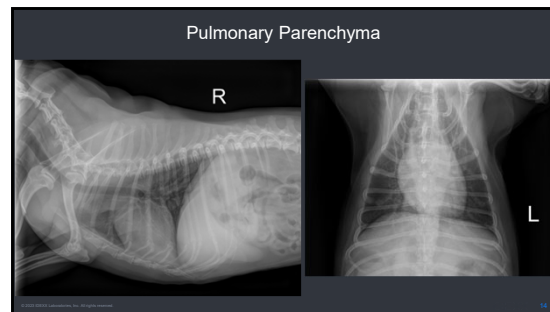
11



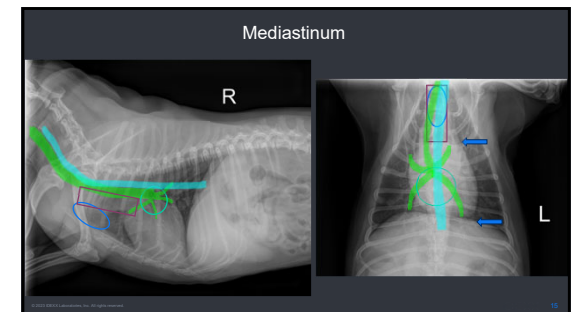
12



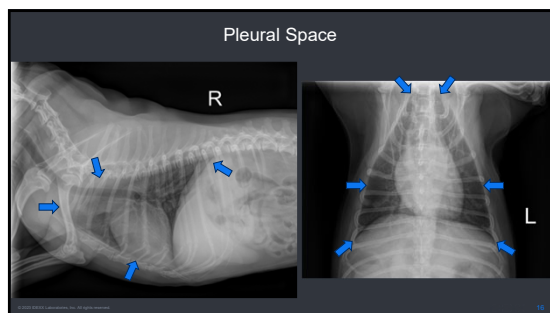
13



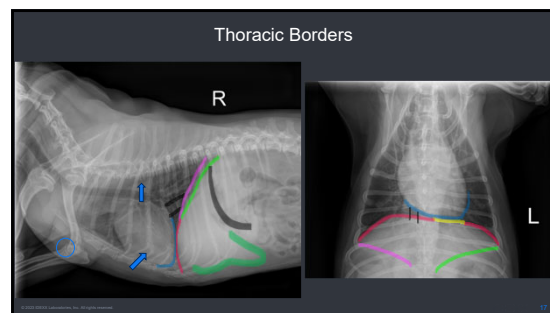
14



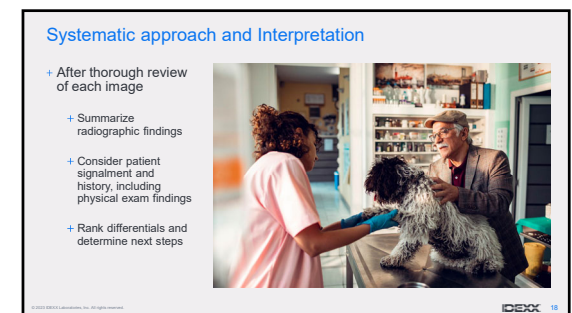15



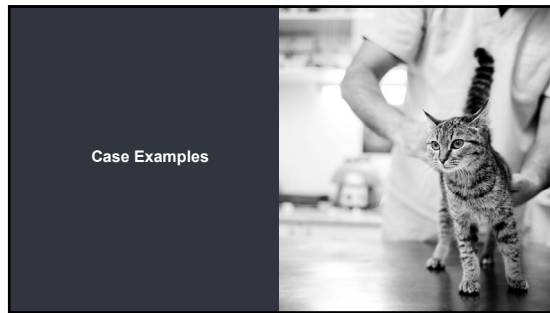
16



17



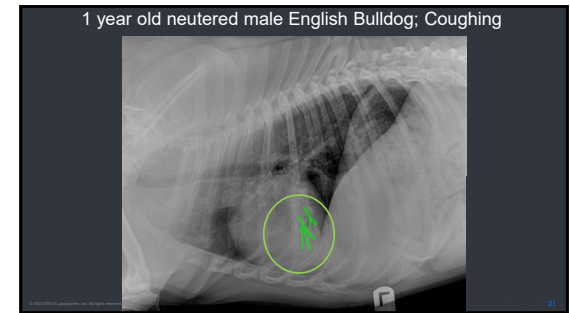
18



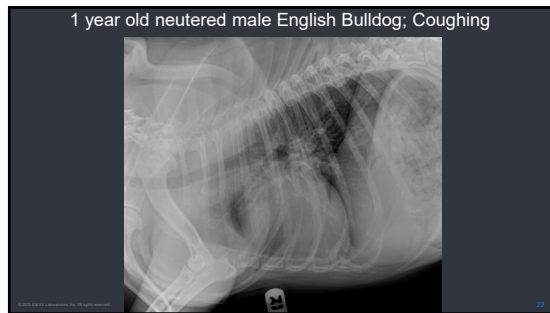19



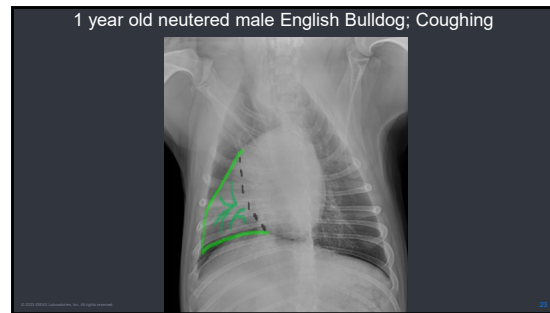
20



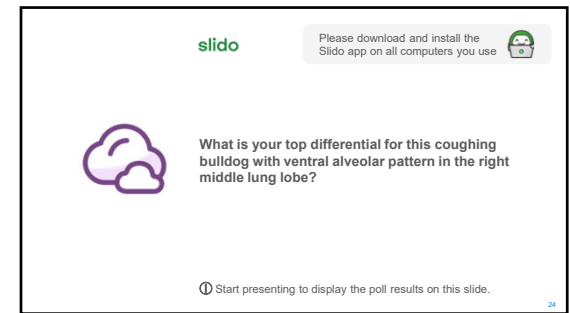
21



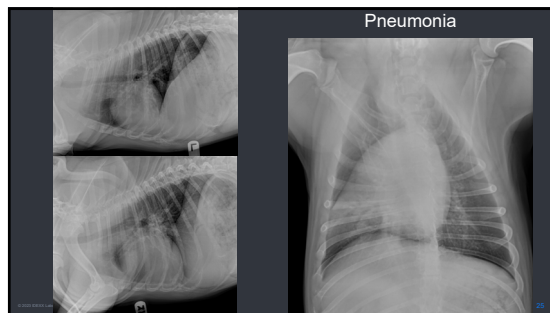
22



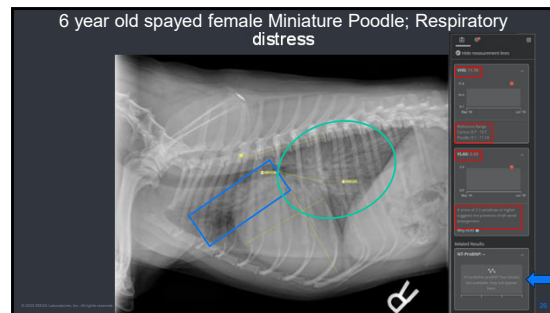
23



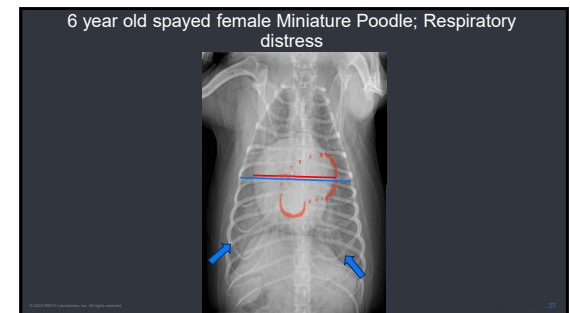
24



25




26



27

slido

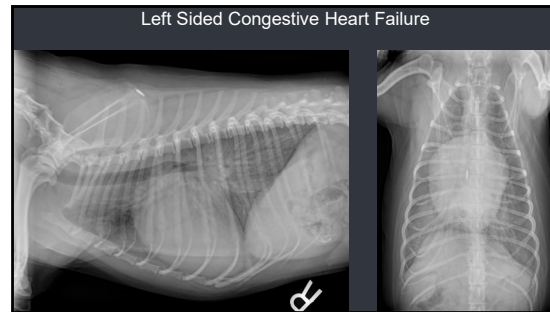
Please download and install the Slido app on all computers you use



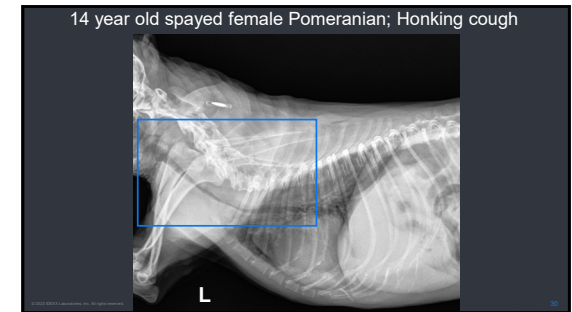
What is your top differential diagnosis for this 6 year old mini poodle in respiratory distress with cardiomegaly, left atrial enlargement, left auricular enlargement, cranial pulmonary vessel enlargement, and caudodorsal unstructured interstitial pattern?

① Start presenting to display the poll results on this slide.

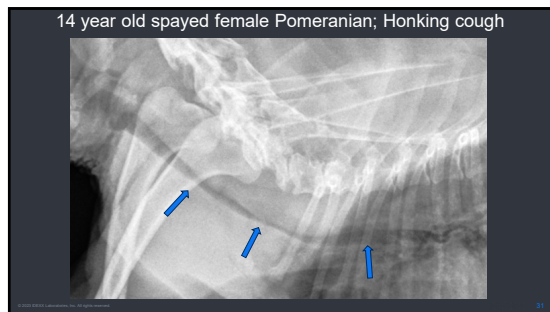
28



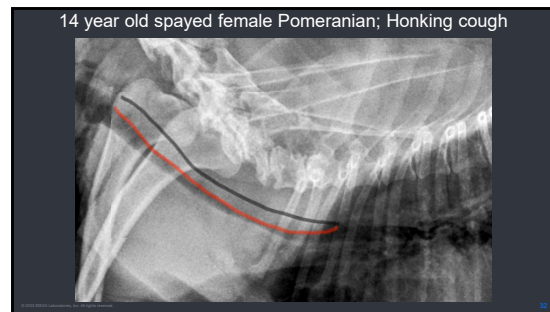
29



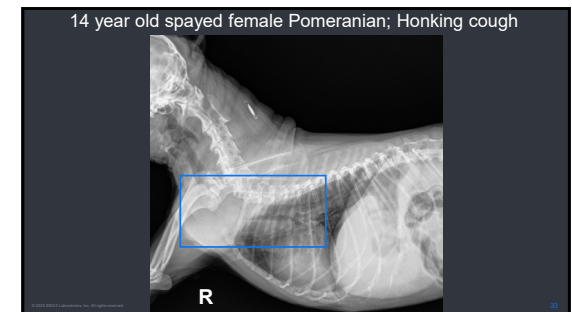
30



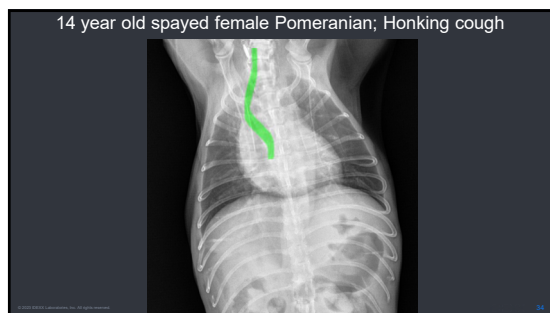
31



32




33



34

slido

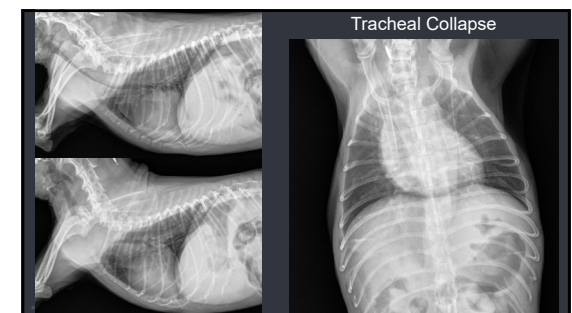
Please download and install the Slido app on all computers you use



What is your top differential for this coughing Pomeranian with a redundant tracheal membrane and varying degrees of tracheal narrowing?

① Start presenting to display the poll results on this slide.

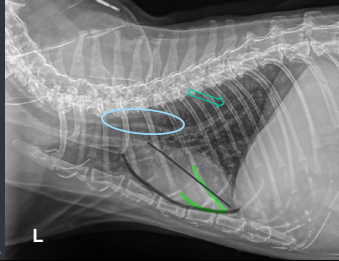
35



36

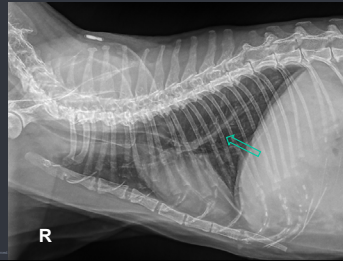


12 year old spayed female domestic shorthair cat; Coughing & wheezing



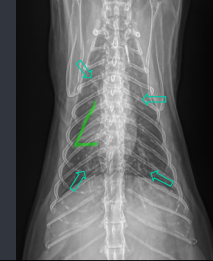37

12 year old spayed female domestic shorthair cat; Coughing & wheezing



38

12 year old spayed female domestic shorthair cat; Coughing & wheezing



39

slido

Please download and install the Slido app on all computers you use

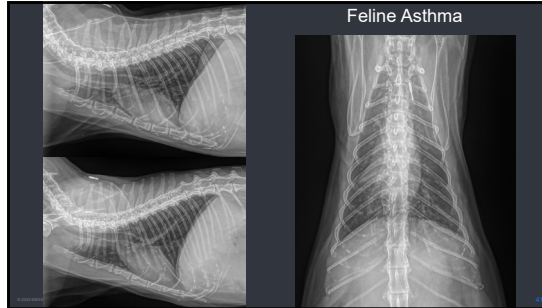


What is your top differential diagnosis for this coughing/wheezing cat with a generalized bronchial pattern and atelectasis of the right middle lung lobe?

① Start presenting to display the poll results on this slide.

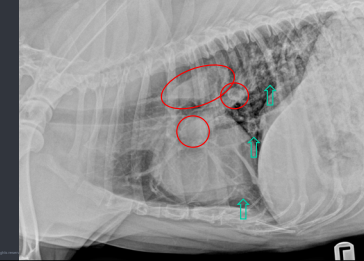
40

Feline Asthma



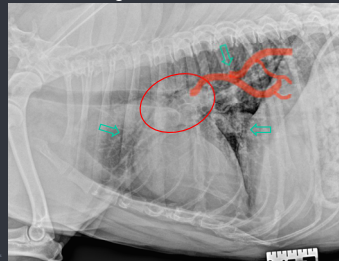
41

Adult neutered male mixed breed dog; Wheezing/mild cough during and after exercise



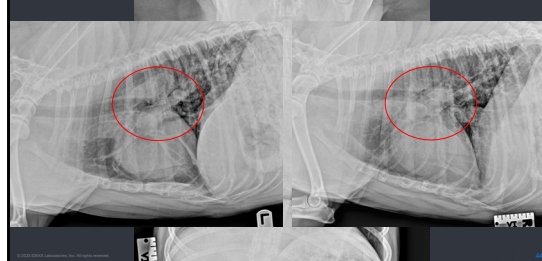42

Adult neutered male mixed breed dog; Wheezing/mild cough during and after exercise



43

Adult neutered male mixed breed dog; Wheezing/mild cough during and after exercise



44

slido

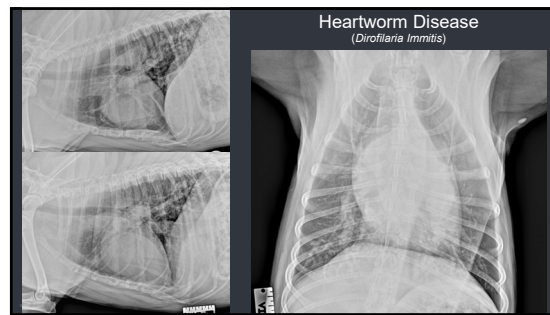
Please download and install the Slido app on all computers you use



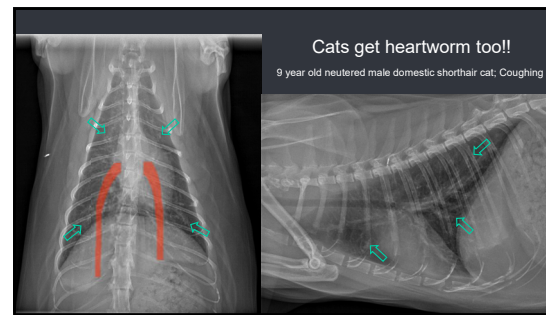
What is your top differential diagnosis for this wheezing/coughing dog with main pulmonary artery enlargement; dilated/enlarged, tortuous, and blunted caudal lobar pulmonary arteries, and a generalized broncho-interstitial pattern?

① Start presenting to display the poll results on this slide.

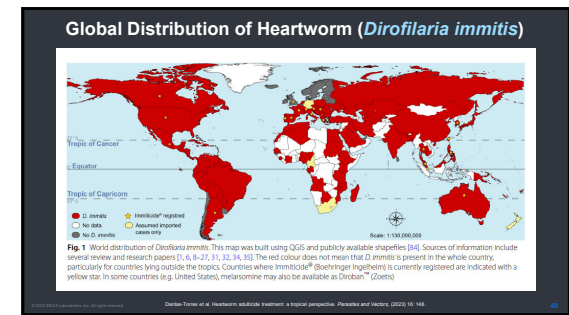
45



46



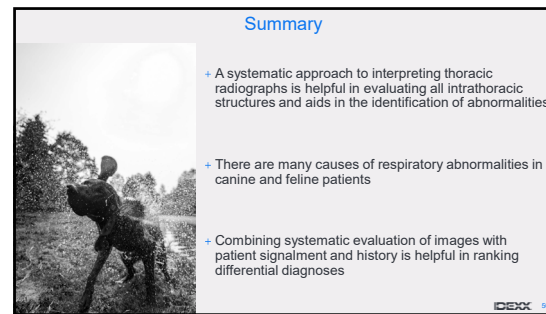
47



48



49



50



51