FALL 2026 • VOLUME XXVIII • ISSUE II

THE CALIFORNIA JOURNAL OF ORAL & MAXILLOFACIAL SURGERY

A PUBLICATION OF THE CALIFORNIA ASSOCIATION OF ORAL & MAXILLOFACIAL SURGEONS



COVER STORY

Artificial Intelligence in Oral and Maxillofacial Surgery

Practical Applications and Future Directions

Mahr Elder, DDS, MD

IN THIS ISSUE

EDITORIAL

Planned Neglect: Why Excellence Requires Subtraction 5
Jeffrey A. Elo, DDS, MS, FACS

PRESIDENT'S MESSAGE

Vivian Jui, DMD, CALAOMS President 7

LEGISLATIVE UPDATE

CALAOMS Advocacy in Action: Building Relationships at the Capitol and in Our Communities 9
Michelle Rivas

OMS PAPERS

Artificial Intelligence in the OMS Practice: Three Pathways for Workflow Implementation 25
Winston Doud, Peter Krakowiak

Defect-Oriented Dual-Segment Acellular Dermal Matrix for Peri-Implant Contour and Keratinized Mucosal Augmentation: A Case Report 30
Pietrangelo S. Vallebuona, Jeffrey A. Elo

PRACTICE MANAGEMENT

Asset Protection for the Oral and Maxillofacial Surgeon 36
Solomon Poyourow, DDS, MD, MPH

CYBERSECURITY

The New Face of Cybercrime: How Hackers Are Targeting Oral Surgery Practices in 2026 44
Paul Murphy

RISK MANAGEMENT

Wrong-Tooth Extraction After Conflicting Referral Documentation 47
Nicole Franklin, MS, CPHRM

www.calaoms.org

Serving those who provide care.

IT'S IN
OUR DNA.



Delivering the best imaginable service and unrivaled rewards is at the core of who we are. As an organization owned and led by physicians for over fifty years, we understand the value of superior care. Because for us, it's not just a best practice, it's in our unique code. Join us at **thedoctors.com**

Exclusively endorsed by
CALIFORNIA ASSOCIATION of
ORAL & MAXILLOFACIAL SURGEONS

Scan here for a rapid premium indication, and discover the unrivaled rewards of The Doctors Company.

50 YEARS

The Doctors Company
TDC GROUP

Artificial Intelligence in Oral and Maxillofacial Surgery: Practical Applications and Future Directions

by Mahr Elder, DDS, MD

In his spring article, "AI in Medicine - Thoughts," Dr. Richard Boudreau raised important questions about accountability, human judgment, and the values that should guide the use of artificial intelligence.[1] These questions have practical implications for oral and maxillofacial surgery (OMS).

Where can AI help us today, and how can we introduce it in our practices?

Artificial Intelligence has quickly moved from science fiction to modern life. People use it to summarize information, draft replies, explain unfamiliar concepts, compare options, and develop creative ideas. Many of us already use AI for work, even if we have not formally integrated it into our practices. A useful starting point is *augmented intelligence*, technology that supports the clinician's work while preserving human judgment and responsibility.

Is it time to take a more deliberate approach to implementing AI? I believe it is.

Available tools offer opportunities to save time, reduce administrative burdens, and improve practice operations. As with any new technology, learning to use these tools effectively requires time, training, and thoughtful oversight. Starting with a few clearly defined applications can help us identify where AI adds value and where its limitations require close human

CONTINUED ON PAGE 21



The California Journal of Oral & Maxillofacial Surgery

A publication of the California Association of Oral & Maxillofacial Surgeons

Board of Directors

Vivian Jui, DMD
President
(949) 727-4633
vivianjuidmd@gmail.com

Nima S. Massoomi, DMD, MD
President Elect
(408) 358-5000
drm@bayareasurgicalarts.com

Kenneth Wong, DDS
Vice President/Secretary
(916) 797-2700
wong.maxface@gmail.com

Jeffrey A. Elo, DDS, MS, FACS
Treasurer and Editor
(909) 706-3910
jelo@westernu.edu

George Maranon, DDS
Immediate Past President
(818) 990-5500
DrM@DrMaranon.com

Peter M. Scheer, DDS, MS
Director
(760) 656-0746
peter@majacholdings.com

Donald R. Liberty, DDS
Director
(916) 941-9860
liberty.maxface@gmail.com

Hooman Adamous, DMD
Director
(562) 866-1111
hoomanadamous@gmail.com

Lauren T. Odono, DDS
Director
(626) 796-4296
lauren.odono@gmail.com

Robyn Alongi
Executive Director
(916) 783-1332
robyn@calaoms.org

Steve Krantzman
Publication Manager
(800) 500-1332
steve@calaoms.org

In This Issue

Cover Story

3 Artificial Intelligence in Oral and Maxillofacial Surgery: Practical Applications and Future Directions
Mahr Elder, DDS, MD

Editorial

5 Planned Neglect: Why Excellence Requires Subtraction
Jeffrey A. Elo, DDS, MS, FACS

President's Message

7 A Message from the President
Vivian Jui, DMD, CALAOMS President

Legislative Update

9 CALAOMS Advocacy in Action: Building Relationships at the Capitol and in Our Communities
Michelle Rivas, CALAOMS Legislative Advocate

AAOMS District VI Report

13 October 2026 AAOMS Trustee Report
W. Frederick Stephens, DDS, FACD, FICD

Year in Pictures

19 2026 Year in Pictures
Advocacy Day, House of Delegates, OBEAM and more

OMS Papers

25 Artificial Intelligence in the OMS Practice: Three Pathways for Workflow Implementation
Winston Doud and Peter Krakowiak, DMD

30 Defect-Oriented Dual-Segment Acellular Dermal Matrix for Peri-Implant Contour and Keratinized Mucosal Augmentation: A Case Report
Pietrangelo S. Vallebuona and Jeffrey A. Elo, DDS, MS, FACS

Practice Management

36 Asset Protection for the Oral and Maxillofacial Surgeon
Solomon Poyourow, DDS, MD, MPH

Cybersecurity

44 The New Face of Cybercrime: How Hackers Are Targeting Oral Surgery Practices in 2026
Paul Murphy, Black Talon Security

Risk Management

47 Wrong-Tooth Extraction After Conflicting Referral Documentation
Nicole Franklin, MS, CPHRM, The Doctors Company

Events

49 Continuing Education & Events
Upcoming live events and on-demand courses

Classifieds

50 Classified Ads
Positions, practices for sale and more

Community

53 California CareForce: Our Impact
Volunteer, donate and follow



ON THE COVER Artificial intelligence is changing how oral and maxillofacial surgeons document, diagnose and communicate. Page 3

Published 2 times a year by the California Association of Oral and Maxillofacial Surgeons. The Association solicits essays, letters, opinions, abstracts and publishes reports of the various committees and members; however, all expressions of opinion and all statements of supposed fact are published on the authority of the writer over whose signature they appear, and are not regarded as expressing the view of the California Association of Oral and Maxillofacial Surgeons unless such statement of opinions have been adopted by its representatives. Acceptance of advertising in no way constitutes professional approval or endorsement. The Editorial Board reserves the right to control article and ad content as well as placement. Changes may be made without notification.

California Association of Oral and Maxillofacial Surgeons©, & CALAOMS© Copyright 2026

CALAOMS also does business as: Oral & Facial Surgeons of California; Southern California Association of Oral and Maxillofacial Surgeons; Southern California Society of Oral and Maxillofacial Surgeons; Northern California Association of Oral and Maxillofacial Surgeons; Northern California Society of Maxillofacial Surgeons; California Society of Oral and Maxillofacial Surgeons; Southern California Oral and Maxillofacial Surgeons.



Planned Neglect: Why Excellence Requires Subtraction

AUTHOR



Jeffrey A. Elo, DDS, MS, FACS
Editor-in-Chief, The California Journal of Oral and Maxillofacial Surgery

A renowned concert violinist was once asked the secret to her extraordinary performances.

Her answer was surprisingly simple: *"Planned neglect. Anything that would keep me from practicing and playing well must be neglected."*

I've thought about that quote many times over the years. At first glance, the phrase sounds harsh. We usually think of neglect as something negative. But that isn't what she meant. She was talking about priorities. She understood that excellence requires more than commitment to what matters most. It also requires the willingness to let go of things that don't.

There's wisdom in that idea, and I suspect many of us could benefit from it. As oral and maxillofacial surgeons, we live in a world that constantly competes for our attention. Emails arrive faster than we can answer them. Meetings fill our calendars. Administrative responsibilities multiply. New opportunities appear before we've finished evaluating the old ones. Add family responsibilities, community commitments, and the endless distractions of modern life, and it's easy to feel as though we're being pulled in a dozen different directions at once.

The problem for most of us isn't a lack of opportunity. It's too much of it.

One of the clearest reminders of this comes whenever we move from one house to another. Only when we're boxing up every possession do we realize how much unnecessary stuff we've accumulated. We find ourselves asking, *Why did I keep this?* The same thing happens in life. Over time, we collect commitments, obligations, habits, and distractions that once seemed worthwhile but no longer serve much purpose. Individually they seem harmless. Together, they become surprisingly heavy.

Every so often, it's worth asking ourselves a simple question: *What am I carrying that no longer needs to be carried?* The answer isn't always comfortable. Sometimes the things slowing us down are not the circumstances we inherited, but the commitments we accepted. We said yes one too many times. We allowed activities of marginal value to occupy space that should have been reserved for things of greater importance.

That's why planned neglect is such a powerful idea. It isn't about caring less. It's about caring more selectively. It means periodically stepping back and asking: *Is this helping me move forward, or is it holding me back? Is it aligned with my purpose, or distracting me from it? Is it adding meaning to my life, or simply taking up space?*

Those questions feel especially relevant today. We live in a culture that often confuses visibility with value. Social media can be a remarkable tool for communication and education, but it has also encouraged the belief that being noticed is the same as making a meaningful contribution.

PLANNED NEGLECT

Three questions worth asking

1	2	3
Is this helping me move forward, or is it holding me back?	*Is it aligned with my purpose, or distracting me from it?*	*Is it adding meaning to my life, or simply taking up space?*

EXCELLENCE IS EARNED THROUGH

Preparation | **Discipline** | **Humility** | **Service**

Fame is fleeting. Public approval is fickle. Entitlement is an illusion. Purpose endures.

Yet surgery teaches a different lesson. Patients do not care how many followers we have. They care whether we are prepared, whether our judgment is sound, and whether they can trust us.

No one is entitled to excellence. No one is entitled to the trust of patients or the respect of colleagues. Those things are earned through preparation, discipline, humility, and service.

Every oral and maxillofacial surgeon knows the sacrifices required to enter this profession. Years of education, training, long nights, difficult cases, missed celebrations, and continuous learning stand behind every credential we hold. The privilege of caring for patients was not handed to us.

It was earned.

Perhaps that's why purpose matters so much. Purpose carries us through difficult days. It keeps us grounded when success comes and steady when it does not. It reminds us why we entered this profession in the first place.

The violinist understood that. Her greatness was not the result of doing everything. It was the result of protecting what mattered most.

Perhaps we would all benefit from a measure of planned neglect. Not as an act of deprivation, but as an act of freedom. The freedom to let go of what is trivial. The freedom to focus on what is meaningful. The freedom to devote ourselves more fully to our patients, our families, our colleagues, our students, and our craft.

As oral and maxillofacial surgeons, we practice a discipline that requires lifelong learning, humility, and continual growth. The challenge before us is not simply to accumulate more knowledge, responsibilities, or accomplishments. It is to maintain clarity about why we chose this profession in the first place.

Because excellence is rarely the result of doing more. More often, it is the result of giving our best attention to the things that matter most. Fame is fleeting. Public approval is fickle.

Entitlement is an illusion. Purpose endures. ■



A Message from the President

AUTHOR



Vivian Jui, DMD
CALAOMS President

As 2026 draws to a close, I find myself reflecting on an extraordinary year and the many lessons it has brought. As I prepare to hand over the presidency, I want to share a few reflections on my experience and thoughts about the future of CALAOMS.

Historically, my involvement with CALAOMS has centered on education, particularly the training of oral and maxillofacial surgery assistants and participation in continuing education planning. My introduction to the legislative side of our organization was an eye-opening experience. With the strong leadership of our Legislative Committee, our Board members, and our lobbyist, Michelle Rivas, I gained a greater understanding of the legislators and proposed legislation that directly affect our specialty. I also became more aware of the efforts of other organizations whose legislative priorities may not align with our profession's best interests.

This experience reinforced an important lesson: *active involvement in CALAOMS is essential to protecting our specialty, our practices, and, most importantly, patient safety*. These issues affect all of us, whether we practice independently or are part of a dental service organization (DSO) or corporate dental practice. I encourage every member to become more involved in our advocacy efforts. If you are unsure where to begin, as I once was, please know that fellow members are ready and willing to help you find your place.

Education remains another cornerstone of our mission. I am pleased to see that our Oral and Maxillofacial Surgery Assistants (OMSA) course continues to thrive. We remain committed to leading the way in the education and training of our assistants, and we welcome your input. *What subjects, skills, or emerging challenges would you like us to address*? Your suggestions will help us ensure that our programs continue to meet the needs of our practices.

Our commitment to patient safety extends beyond the walls of our own offices. Many of you may know general dentists or other specialists who utilize anesthesia providers in their practices. CALAOMS recognizes the importance of ensuring that dental assistants in these settings also receive appropriate training to support safe anesthesia care. We are preparing to launch an initiative to provide this training, representing another important step in our ongoing commitment to patient safety and professional leadership.

Our Continuing Education Committee has also expanded its offerings, introducing seven webinar programs this year. These included a three-part cybersecurity series, a three-part Office Managers Forum series, and a planned webinar on investment management. These programs complement our popular online library of infection control and Dental Practice Act courses. We are continually looking for ways to provide relevant, practical education for our members. Please share your ideas and suggestions for future programs so we can continue to develop offerings that address your needs.

CALAOMS headquarters has been equally busy. Our new Executive Director, Mrs. Robyn Alongi, has played an instrumental role in refreshing the look and feel of our communications. Under her leadership,



CALAOMS has established a stronger social media presence, including Facebook and Instagram, and updated its communications graphics to create a more consistent and professional appearance. I encourage you to follow us on social media and stay connected with the latest news and activities.

We also extend our best wishes to Communications Director Steve Krantzman as he retires, with sincere appreciation for his contributions to CALAOMS. And we want to recognize Teri Travis, whose dedication to our Continuing Education Committee has made her a familiar and valued presence to many of our members. Teri will enter her final year with CALAOMS in 2027, and we are grateful for her continued service and commitment.

As I pass the gavel to my successor, Dr. Nima Massoomi, I do so with great confidence in the future of CALAOMS. Having worked with Dr. Massoomi for many years, I know him to be thoughtful, insightful, and committed to our specialty. Our organization will be in excellent hands under his leadership.

Serving as your president has been a rewarding experience, and I am grateful for the opportunity to contribute to an organization that works so diligently to advance and protect our profession. I encourage you to remain engaged, take advantage of the educational opportunities CALAOMS offers, and consider how you, too, can contribute to our collective success.

I look forward to seeing you at an upcoming continuing education conference or committee meeting. Thank you for allowing me to serve. ■

Vivian Jui, DMD, CALAOMS President



CALAOMS Advocacy in Action: Building Relationships at the Capitol and in Our Communities

AUTHOR



Michelle Rivas
CALAOMS Legislative Advocate

The California Association of Oral & Maxillofacial Surgeons (CALAOMS) has continued to strengthen its advocacy efforts throughout the year. From Advocacy Day and legislative engagement to political involvement and grassroots outreach, each component of CALAOMS' advocacy program is designed to educate policymakers, build relationships, and increase understanding of the unique role oral and maxillofacial surgeons play in California's healthcare system.

Advocacy Day at the State Capitol

In April, CALAOMS members traveled to Sacramento for Advocacy Day, meeting directly with legislators and legislative staff to discuss issues impacting the practice of oral and maxillofacial surgery and patient access to care.

An important part of these meetings was educating policymakers about what distinguishes an oral and maxillofacial surgeon (OMS) from a general dentist. CALAOMS members discussed the extensive education and post-doctoral surgical training required to become an OMS, as well as their experience in anesthesia and hospital-based care. Members also highlighted the broad scope of OMS practice, including facial trauma surgery, corrective jaw surgery, pathology, and the safe administration of anesthesia.

These conversations are particularly important because many legislators and staff are unfamiliar with the significant differences in education, training, and scope of practice between an OMS and a general dentist. Advocacy Day gives our members an opportunity to tell that story directly and demonstrate why OMS must have a voice in healthcare policy discussions.

Taking Advocacy into OMS Offices

Our advocacy does not end when members leave the Capitol. CALAOMS continues to expand its grassroots efforts through the Key Person Program and in-district OMS office visits with legislators.

The OMS office tours provide an important opportunity for legislators and staff to see firsthand the sophisticated clinical environment in which OMSs practice and to better understand the complex surgical procedures, anesthesia services, technology, equipment, and patient care provided every day.

Just as importantly, office tours provide an opportunity for legislators to develop relationships with OMSs who live and practice in their districts. Those constituent relationships are an

essential part of effective grassroots advocacy. When an issue affecting OMS comes before the Legislature, we want policymakers to understand the profession and know that they have a trusted local resource they can contact for information.

CALAOMS will continue scheduling these visits and encourages members interested in hosting a legislator to participate in the Key Person Program.

CALAOMS PAC Interviews Legislative Candidates

CALAOMS' advocacy program engages in the political process through the CALAOMS PAC.

Following the primary election, the CALAOMS PAC Board met to interview several candidates running for seats in the California State Legislature. These interviews provide the Board with an opportunity to learn more about the candidates, their backgrounds, priorities, and approach to public policy while giving CALAOMS an important opportunity to educate individuals who may soon be serving in the Legislature.

During the interviews, candidates learned about the unique education and training of oral and maxillofacial surgeons, the intersection of medicine and dentistry within the specialty, and some of the legislative and regulatory issues affecting OMS practices and their patients.

Candidate interviews are an important component of the PAC's work because political engagement is about more than making contributions. It is about establishing relationships and educating future policymakers before they arrive at the Capitol. The interviews also help the PAC Board make informed decisions about endorsements and political support.

Advocacy Is a Year-Round Effort

Advocacy Day, legislative lobbying, the CALAOMS PAC, the Key Person Program, and OMS office tours are not separate efforts, they are all part of a coordinated advocacy strategy.

Our goal is to build relationships with legislators at every stage: educating candidates before they are elected, meeting with lawmakers at the Capitol, connecting legislators with OMS constituents in their districts, and inviting policymakers into OMS practices so they can see firsthand the specialized care CALAOMS members provide.

These relationships become particularly important when legislation or regulatory proposals arise that could affect the profession or patient care. The more policymakers understand OMS before an issue reaches their desk, the stronger CALAOMS' voice will be when it matters.

As we look toward a new legislative session, CALAOMS will continue building on these efforts and creating additional opportunities for members to become involved. Whether through Advocacy Day, hosting an office tour, developing a relationship with a local legislator, participating in the Key Person Program, or supporting the CALAOMS PAC, member involvement is what makes our advocacy program successful. Advocacy is not a single day at the Capitol; it is the relationships we build throughout the year.

Below is a summary of the bills on which CALAOMS took a position during the 2025–26 legislative session and their final disposition:



In-Office Tour: Dr. Don Liberty and Assemblyman Josh Hoover touring Dr. Liberty's oral surgery office

AB 1629 (Haney) – Assignment of Benefits / Dental Coverage - Position: Support

Requires a health care service plan (health plan) or health insurer to pay a non-contracting dental provider or registered dental hygienist in alternative practice directly for covered services if the non-contracting provider submits a written assignment of benefits (AOB) form signed by the enrollee. Requires a non-contracting provider to disclose specified information on out-of-pocket costs to the patient and obtain signed and dated consent to an AOB.

As expected, Delta Dental and the health plans strongly opposed the bill, arguing that mandatory assignment of benefits could discourage dentists from participating in provider networks, increase patient out-of-pocket costs, and weaken consumer protections. They also raised concerns that the bill could improperly treat predeterminations as guaranteed payments before final eligibility, coverage, and other claim factors are verified.

Despite their opposition, the bill received strong support.

Status: *Governor Newsom signed AB 1629 in September 2026.*

AB 1717 (Castillo) – Medi-Cal Dental Reimbursement for House/Extended Care Facility Visits - Position: Support

Requires DHCS to increase Medi-Cal reimbursement for dental house calls to a minimum of $120 per visit, with adjustments every two years for inflation and provider costs, and to report on the impact on access to care, utilization, and dental-related emergency department visits.

To reduce costs and administrative burden on DHCS, the bill was amended to remove the $120 minimum reimbursement rate, biennial rate adjustments, and reporting requirements, allowing the rate to be set consistent with other Medi-Cal dental service codes. The bill had no opposition and despite the author's efforts to address cost concerns the bill failed.

Status: *Held in Assembly Appropriations.*

AB 1760 (Arambula) – Dental Practice Act Cleanup / Regulatory Changes - Position: None

The bill makes several changes to the Dental Practice Act update touching licensure, examination standards, assistant duties, educational oversight, and facial cosmetic surgery permitting. Much of the bill was administrative or technical.

AB 1760 streamlines the Elective Facial Cosmetic Surgery Permit by eliminating procedure-specific limitations within permit categories. This is intended to create a clearer permit structure based on an OMS's demonstrated training and competency to perform one or both categories of elective facial cosmetic surgery.

The bill received no opposition and enjoyed strong bi-partisan support. Status: Approved by Governor Newsom August 31, 2026.

AB 1952 (Berman) – Dental Hygienist Licensure Pathway - Position: Support

This measure creates an alternate pathway for qualified internationally educated dentists to become licensed dental hygienists in California. At a time when workforce access remains a challenge, this bill reflects a pragmatic approach to expanding the provider pipeline while maintaining licensure safeguards.

"At a time when workforce access remains a challenge, this bill reflects a pragmatic approach to expanding the provider pipeline while maintaining licensure safeguards."

The California Dental Association sponsored the bill noting that the bill seeks to address dental workforce shortages by creating a faster pathway for internationally trained dentists to become licensed dental hygienists in California and provide dental hygiene services while pursuing dental licensure.

The California Dental Hygienists' Association and Dental Hygiene Board of California opposed the bill, arguing that internationally trained dentists should be regulated by the Dental Board of California through a restricted dental license rather than licensed as dental hygienists by the Dental Hygiene Board.

Status: *Held in Assembly Appropriations Committee.*

AB 2029 (Sharp-Collins) – Dental Carrier Transparency - Position: Support

Requires dental plans and insurers to establish online portals that provide both contracted and noncontracted dental providers with real-time patient eligibility, coverage, reimbursement, and estimated out-of-pocket cost information at the procedure-code level. The portals must also allow providers to submit claims and supporting documentation, track claim status and payments, and receive detailed denial information. Portals must be HIPAA compliant, available 24/7 except for maintenance, and provided to treating dental providers at no cost.

CDA sponsored the bill, arguing that requiring dental plan portals to provide standardized, comprehensive benefit information would allow dental offices to more accurately estimate coverage and patient out-of-pocket costs. Dental plans opposed the bill, arguing that the requirements are unnecessary, could increase costs, limit innovation, conflict with developing technology standards, and undermine the value of provider networks by extending portal access to non-participating providers.

Status: *Hearing in Assembly Health was canceled at the author's request.*

AB 2625 (Solache) – Foreign Dental Schools - Position: Support

This bill would maintain the approval of certain foreign dental schools previously approved by the Dental Board while they pursue accreditation through CODA or another approved accrediting body. The bill also protects licensure eligibility for graduates who enrolled in an approved

2026 LEGISLATIVE SESSION

Bills at a glance

BILL	ISSUE	CALAOMS	OUTCOME
AB 1629	Assignment of Benefits / Dental Coverage	Support	• **Signed into law (Sept. 2026)**
AB 1717	Medi-Cal Dental Reimbursement for House/Extended Care Facility Visits	Support	• Held in Assembly Appropriations
AB 1760	Dental Practice Act Cleanup / Regulatory Changes	None	• **Signed into law (Aug. 31, 2026)**
AB 1952	Dental Hygienist Licensure Pathway	Support	• Held in Assembly Appropriations
AB 2029	Dental Carrier Transparency	Support	• Hearing canceled at author's request
AB 2625	Foreign Dental Schools	Support	• Not set for hearing
AB 2746	Medical Debt / Medical Credit Cards	**Oppose**	• Held in Assembly Banking & Finance
SB 1311	Dental Assistants / Infection Control Training	Support	• **Signed into law (Sept. 14, 2026)**
SB 1416	Duplicate Payment Refund Timeline	Support	• In Assembly Appropriations

• Became law • Opposed bill held • Did not advance

foreign dental school even if the school's approval expires before they graduate, and requires schools with maintained approval to provide regular updates on their accreditation status.

Status: *Referred to Assembly Business & Professions, but not set for hearing.*

AB 2746 (Schiavo) – Medical Debt / Medical Credit Cards - Position: Oppose

One of the more concerning proposals this year. While framed as consumer protection, AB 2746 would create significant privacy, operational, and practical problems by redefining medical debt to include third-party financing products. Determining whether a charge qualifies would require access to sensitive protected health information, raising serious HIPAA and patient trust concerns.

This was a major advocacy priority for CALAOMS, and coalition opposition proved effective.

Status: *Held in Assembly Banking & Finance Committee. We have heard the author may attempt to bring the concept back next year.*

SB 1311 (Wahab) – Dental Assistants / Infection Control Training - Position: Support

SB 1311 creates more flexibility in how dental assistants satisfy infection control training requirements while preserving employer accountability and patient safety standards.

Dental assisting and hygiene organizations opposed the bill, raising concerns that it reduces Dental Board oversight and eliminates required hands-on infection control training. They argued that unlicensed dental assistants should receive and demonstrate hands-on infection control training under the supervision of a dentist or other qualified licensed dental professional before working with patients.

Status: *Governor Newsom signed SB 1311 on September 14, 2026.*

SB 1416 (Wahab) – Duplicate Payment Refund Timeline - Position: Support

This bill shortens the timeline for refunding duplicate patient payments from 30 days to 21 days. While operationally manageable, it does tighten compliance expectations for providers.

The bill passed the Senate with unanimous approval and was recommended for consent in the Assembly Appropriations Committee but was not taken up.

Status: *Assembly Appropriations Committee.*

Please don't hesitate to contact me if you have any questions.

Thank you. ■



October 2026 AAOMS Trustee Report

AUTHOR



W. Frederick Stephens, DDS, FACD, FICD
Diplomate, American Board of Oral & Maxillofacial Surgery

AAOMS District VI Trustee

Greetings from your AAOMS District VI Trustee:
November, 2026

Well, we are past summer and the Holidays are on the way! Gee's it goes by faster and faster every year! Hopefully, you'll find some time to enjoy yourself with friends and family this holiday season.

BREAKING NEWS: I am honored and enthusiastic to announce my candidacy for AAOMS Vice-President for 2027. *I am humbled to have the support and encouragement of many of my colleagues to seek this office and grateful for the opportunity to continue to contribute to our Associations leadership and future direction. I look forward to this new journey and welcome your input as to how* ***together****, we can advance AAOMS and rekindle the passion that drew us into our profession. I will be visiting several regional and state meetings this year to present myself and discuss my view of the future landscape for AAOMS. I also am asking for input from our national members as to how we can make our Association and Specialty better. If you wish, you can learn more at* **StephensForAAOMSVP.com**.

I am well into my 6th and last year as your **AAOMS District VI Trustee**. I continue to be extremely grateful and humbled for the confidence you all have shown me, by re-electing me in the 2025 House of Delegates, to this important and rewarding position. I will continue, to represent all your interests at the AAOMS Board level, to the best of my ability, for the remainer of my term.

We, at AAOMS, have been very busy with president **Dr. Robert S. Clark** at the helm. Given his many years in private practice, his four years as AAOMS Treasurer, and his experience on The Board, he has represented our AAOMS membership this year with skill, insight, and a lot of *"Clark Wit"*. **Dr. Charles A. Crago** has now taken the reins, as of the 2026 House of delegates. He hit the ground running, addressing a contentious anesthesia issue at the recent ADA house of Delegates. I have known Chuck for years and I know that Dr. Crago will serve you well this coming year and make us all proud.

Our Board of Trustee's (BOT) continues to be occupied by extremely sharp members with diverse viewpoints, who all strive towards the collective goal of our AAOMS mission. Together with our fantastic senior management team and their support staff, the AAOMS is strong and remains a highly recognizable and respected entity in healthcare.

Another very important group representing our Western States, who deserve **special thanks**, is all our dedicated delegates and alternates, who represent us at the AAOMS House of Delegates. This is where AAOMS governance begins and ends. The Western Society of Oral & Maxillofacial Surgeons / WSOMS is critical in organizing our states and their delegates at our summer caucus and the House of Delegates, at the AAOMS annual meeting. Being a member of the WSOMS and therefore, supporting their mission, is your obligation to your specialty and your region. **It is a well**

spent $50.00 / year! Thank you to all our WSOMS members!

I hope to see you at the **Dental Implant Conference / DIC in Chicago December 3-5th, 2026**. *Please note;* next year (2027), the **DIC** will be in **Orlando, FL**., for a *"warmer"* experience. More details can be obtained through **AAOMS.org**.

Please remember, as your Trustee, I am still your portal of communication to the AAOMS - your specialties national association. **Please utilize me***!* You can contact me via E-mail at dr.wfstephens@gmail.com or if urgent, call me on my cell at (626) 353-4575.

Finally, if you are pondering expanding your professional experience by entering leadership in your state or at a national level, *please give your state societies' Executive Director, State Board members, … or me, a call or e-mail.* We are always looking for new people with new perspectives, to advance our specialty. **This can be a very rewarding experience and prove to be the apex of your career!**

Again, thank you for your continuing confidence and support.

W. Frederick Stephens, DDS

FACD, FICD

AAOMS, District VI Trustee

dr.wfstephens@gmail.com

PRIORITY INFORMATION POINTS

- **AAOMS Updates Governing Documents:** The 2026 HOD approved a modern rewrite of the Association's Governing Rules and Regulations, published as the *Governing Documents,* is now available on AAOMS.org/resources.
- **AAOMS membership dues:** Statements mailed in October and are due by **Dec. 15, 2026**. The mailing included verifications for AAOMS.org and MyOMS.org directories. Only members who opt-in for inclusion on MyOMS.org will find their business addresses listed. Contact membership@aaoms.org for additional assistance.

"We are always looking for new people with new perspectives, to advance our specialty."

- **JOMS Article on OMS Anesthesia Safety:** In October, JOMS published **Training Matters: Why Competency Should Guide Office-Based Pediatric Anesthesia Policy**, a Special Contribution article authored by the AAOMS Board of Trustees and past presidents summarizing training and available data, which support the safety of the OMS team-based model of anesthesia delivery. **Please read this article.**
- **Anesthesia Advocacy at the ADA:** At the Oct. 8-13 ADA House of Delegates meeting, an ADA District 17 (Florida) resolution requested adoption of proposed ADA *Guidelines for the Use of Sedation and General Anesthesia by Dentists for Pediatric Patients* which would have recognized both the OMS team-based model – when provided by appropriately trained specialists – as well as the separate anesthesia provider model for the administration of anesthesia for pediatric patients. Despite valiant efforts by OMSs serving on the ADA HOD and AAOMS leadership, the ADA House referred the resolution for consideration in 2027. Mindful that several states incorporate ADA guidelines by reference, AAOMS will continue to work through appropriate ADA committees and other avenues to advocate for ADA recognition of the OMS team-based model.
- **Federal Court Decision on Specialty Advertising**: In July, a South Dakota federal court issued an order declaring as unconstitutional a state regulation that required dentists to have completed at least two years of full-time training in an accredited residency program to call themselves specialists. This effectively allows dentists in South Dakota to call themselves specialists in dental implantology. The decision may affect similar laws and regulations in other states.
- **OMSs on State Dental Boards:** The AAOMS Strategic Plan calls for getting an OMS on every state dental board. From anesthesia to scope of practice, these boards make decisions that can significantly impact how we care for patients. If OMSs don't have a voice at the table, these decisions could be made without our expertise — or worse, to our detriment. We encourage you to get involved, whether it's serving on your state's dental board, joining an anesthesia or scope committee, or even just attending meetings and submitting comments. And if you do, let AAOMS know at advocacy@aaoms.org. We have resources, talking points and staff to support your efforts.
- **AAOMS** has launched the **Milestones Campaign**, a national public health initiative in partnership with the **ADA** and **AAO** to educate parents on key oral health milestones at **ages 1, 7 and 15**. The campaign promotes timely visits to dentists and dental specialists and features nationwide TV and radio public service announcements. Learn more and watch the video at MilestonesMet.org. Members are encouraged to become campaign ambassadors and download the toolkit at AAOMS.org/Milestones.
- Follow the **AAOMS LinkedIn account** at LinkedIn.com/company/AAOMS to learn about the latest news about the Association's initiatives, publications and offerings. The account on the business-focused social media platform has more than 15,000 followers who can read about the latest JOMS research, advocacy updates, podcasts, CE courses and more.
- **The 2026 Dental Implant Conference / DIC** will be held at the Sheraton Grand Chicago Riverwalk, **Chicago, December 3-5, 2026**. The major theme is; **Implant Truth Wars; What We Think We Know vs. What the Data Actually Shows. Registration is open now. Don't miss this one.**

The 2027 Dental Implant Conference / DIC will be held in **Orlando, December 2-4,2027**. Please look forward to the change in location.

- **Day on the Hill:** Last year was its **25th Anniversary** and it brough together approximately 100 OMSs and residents to advocate on student debt relief, dental insurance reform, and coverage for congenital craniofacial anomalies. Please put the **26th Anniversary Day on the Hill, March 16-17th, 2027** on your schedule.

Attendance can be a very eye opening & rewarding experience for you. **Please come and see how the "sausage is made" in DC**.

- At the **2026 AAOMS House of Delegates**, **Resolution 26-B-5,** *(RESOLVED, that AAOMS remove the current deadline and membership requirement for completion of an approved OMS simulation course, by rescinding Resolution 20-B-5)* passed with a greater than 2/3rds vote by the HOD's. As a result, simulation training is still strongly advocated and recommended for any member providing the OMS Anesthesia Team model of patient care, although is no longer is a requirement for AAOMS membership.

"Members are encouraged to become campaign ambassadors and download the toolkit at AAOMS.org/Milestones."

- For those members who have previously completed OBEAM simulation training, **opportunities for free CE** will be announced soon this year. All who have competed OBEAM as per the previous membership requirement, will be contacted with the details. **Thank you to those members and fellow who recognized the importance of simulation training in the interest of patient safety**.
- **AAOMS's** member-facing podcast series – **AAOMS On the Go** – publishes new episodes twice a month. The podcasts can be downloaded or streamed at **AAOMS.org/Podcasts** or popular platforms such as Apple Podcasts, iHeart and Spotify. Topics cover research, advocacy, affiliate organization news, JOMS, practice management and more. We encourage members to listen and submit topics and speakers for future podcasts.

Questions and suggestions can be submitted to*;* **communications@aaoms.org.**

- Follow the **AAOMS LinkedIn account** at *LinkedIn.com/company/AAOMS* to learn about the latest news about the Association's initiatives, publications and offerings. The account on the business-focused social media platform has more than **15,000 followers** who can read about the latest JOMS research, advocacy updates, podcasts, CE courses and more.

MORE INFORMATION

Anesthesia and Patient Safety

- **AAOMS** continues to collect data from third-party sources, including private insurance claims, to support advocacy for the OMS anesthesia team model.
- Members are encouraged to report adverse events through the **Dental Anesthesia Incident Reporting System** (DAIRS*): AAOMS.org/DAIRS.*

OBEAM at State and Regional Society Meetings

- Despite the passage of Resolution 26-B-5 at the 2026 HOD's, difficult airway simulation training is still strongly advocated for by AAOMS and continues to be available for member training.
- **State and regional OMS societies can host** the Office-Based Emergency Airway Management *(OBEAM)* module.
- This **two-hour, hands-on session** covers airway management techniques including BVM, LMA insertion, and endotracheal intubation using **Airtraq**.
- **Up to 10 surgeons per session** can train using **AAOMS** Laerdal 3G simulators.

VOLUME 28, Nº 2 · FALL 2026

AAOMS DISTRICT VI

- **Registration is $925** per OMS and includes **6 CE hours**. **AAOMS** handles registration and provides equipment, staff, and facilitators.
- **For more information**, contact **Mary Allaire-Schnitzer at 800-822-6637 ext. 4315 or mallaire@aaoms.org.**

Education/Events

CE Online:

- **Clinical CE Subscription**: Access more than 150 hours of on-demand clinical CE for $449 per year. Includes 20+ new courses annually. Learn more at *AAOMS.org/CESubscription*.
- NEW! Practice Management Subscription: Access more than 30 hours of on-demand practice management CE for $449 per year. Learn more at *AAOMS.org/PMSubscription*.
- Members have the option to bundle both the clinical and practice management subscriptions to **save $100**.
- **2027 Annual Meeting:** The **2027 AAOMS Annual Meeting, Sept. 20 – 25** *will be held in* **San Antonio, TX.** Please begin to make plans for the **109th AAOMS Annual Metting and Scientific Sessions**.
- **OBEAM 2026**: Hands-on emergency airway management training is offered at the Daniel M. Laskin Institute for OMS Education and Innovation at **AAOMS** headquarters in Rosemont, Ill. $925 for AAOMS members/fellows. Visit *AAOMS.org/OBEAM*.
- **Upcoming Webinars:** See the schedule at *AAOMS.org/webinars*.
- **Webinar Bundles**: Two coding and billing bundles available for $495 each – **save 35%.**
- **Meetings & Events:** Explore all upcoming AAOMS educational opportunities at **AAOMS.org/Events.**
- **Coding Certificate Program (CCP)**: Get Introduction to Insurance Coding and Billing, OMS Coding Essentials: Medical and Dental Procedures and Diagnoses and OMS Billing Essentials: Navigating the Insurance and Reimbursement System in one discounted bundle. Visit AAOMS.org/CCP.
- **DEA/MATE Act Training**: Free to members. Fulfills training for DEA license renewal: DEA Requirement Info. Register at **ceonline.aaoms.org/MATEAct**.

> "The AAOMS Mentor Program is available to dental students, residents and surgeons considering a practice change."

Governance and Membership

- Support your professional staff and save – learn more about **allied staff membership** *AAOMS.org/AlliedStaff* or email *membership@aaoms.org*.
- The **AAOMS Mentor Program** is available to dental students, residents and surgeons considering a practice change. Visit **AAOMS.org/Mentorship** for more information or complete an application to become a mentor.

Federal Advocacy

- **Day on the Hill:** Last year was its **25th Anniversary** and it brough together approximately 100 OMSs and residents to advocate on student debt relief, dental insurance reform and coverage for congenital craniofacial anomalies. Please put the **26th Anniversary Day on the Hill, March 16-17th, 2027** on your schedule.

Attendance can be a very eye opening & rewarding experience for you. **Please come and see how the sausage is made**.

- **Federal Legislation Update**: **AAOMS** advocates on drug shortages, provide student loan relief and require health insurance coverage for patients with congenital craniofacial anomalies. Add your voice to these efforts at *AAOMS.org/TakeAction*.
- **Federal Regulatory Efforts**: AAOMS commented on several proposed federal regulatory initiatives, including tariffs on pharmaceutical products and medical devices and supplies, new student loan limits and the elimination of the Grad PLUS Loan program, proposed changes to the Public Service Loan Forgiveness program, and an exemption for healthcare workers from new H1B visa fees.
- **Recruitment Resource**: A video on oral surgery assisting is available to help OMSs attract potential assistants. View it at *AAOMS.org/OralSurgeryAssistant*.
- **Medicare Dental Claims**: Since July 1, diagnosis codes and modifier KX are required to show medical necessity. Use modifier GY for denial-only claims. For more information related to Medicare dental claims, refer to the *AAOMS Medicare FAQs* on *AAOMS.org*.
- **2026 Medicare Payment Updates**: CMS increased hospital outpatient and ASC rates by 2.6% and the facility fee for G0330 to $3,387.27 in the hospital outpatient setting and $1,480.50 in ASCs. The hospital inpatient-only list will be phased out over 3 years, making more services payable in outpatient and ASC settings. On the other hand, CMS implemented a 2.5% efficiency cut to work RVUs and reduced facility PE RVUs to half of non-facility PE RVUs.
- **No Surprises Act**: **AAOMS** is closely monitoring developments. Resources are at *AAOMS.org/practice- resources/coding-reimbursement*.
- **OMS Action Network**: Get involved in grassroots advocacy. Text **"AAOMS" to 50457** for alerts and **take action** on current campaigns at *AAOMS.org/TakeAction*.

State Advocacy

2026 Wins:

- **State Advocacy Efforts in Q1 2026: Q1 AAOMS** supported the Washington State Society of Oral & Maxillofacial Surgeons / WSSOMS – in coordination with the Washington State Dental Association / WSDA – to successfully oppose a legislative proposal – SB 6138 - that would have required a separate anesthesia provider for every dental patient receiving deep sedation/general anesthesia. **A special thank you goes out to Dr. Lisa Egbert, as the WSDS President, for her advocacy efforts in this matter.**

Later recent meetings with Washington State Senator Jeffery Holy (author of SB6138), were very productive in October. This issue/legislation may return in the 2027 Washington State legislative session …

- Meanwhile, legislation (HB 2906) is advancing in **Arizona** to mandate a seat on the dental board for an OMS. **AAOMS** also continues to work with state OMS societies and other organizations in matters of specialty recognition, CRNA scope, insurance, imaging accreditation, and more.
- **Tracking Tool**: Follow key state legislative issues on the *State Legislative Tracking Map*.
- **State Advocacy Grant**: State societies facing OMS-specific challenges can apply for matching grants at *AAOMS.org/SAG*. All grants have been distributed for 2026, but special requests may be submitted for BOT consideration.

> "Relationships with lawmakers make a difference, and reporting these connections back to AAOMS strengthens the specialty's collective advocacy."

OMSPAC

- **OMSPAC:** New recognition levels in 2026: **Bronze** ($300), **Silver** ($500), **Gold** ($1,000), **Platinum** ($2,500), and **Capital Club** ($5,000). A $50 **Early Career level** will remain in effect for OMSs who are within two years post-residency. Visit *OMSPAC.org*.
- **District V** won the 2026 HOD's challenge. **This makes District VI look BAD**, especially given the **HOD's challenge** was created by a past (District VI) OMSPAC Chair! **Let's win it next year!!**
- **Congressional Key Contact:** Oral and maxillofacial surgeons play a crucial role in shaping the future of their specialty. By becoming a key contact for members of Congress, members can directly influence healthcare policy, protect the profession and ensure patients continue to receive the care they need. Relationships with lawmakers make a difference, and reporting these connections back to AAOMS strengthens the specialty's collective advocacy. Join the **Capitol Contact Campaign to help build stronger ties on Capitol Hill and advance the issues that matter most. To get involved, reach out to advocacy@aaoms.org.**

Informational Campaign

- **MyOMS.org** continues to grow in popularity – with about 1.5 million page views each year and more than 100,000 visitors to the website using the Find a Surgeon function.
- **More than 350 videos and 24 infographics** are featured on the MyOMS.org website and are available for members to download and use on their practice sites. Visit *AAOMS.org/InfoCampaign*.
- AAOMS continues to get a lot of free advertising *(total broadcast audience of 1.4 billion)* from **seven TV Public Service Announcements** – with a cumulative equivalent ad dollar value of more than **$36.1 million**; and radio PSAs have generated an equivalent ad dollar value of more than **$5.4 million**.
- A public-facing podcast series – **OMS Voices: An AAOMS Podcast** – debuted in 2023. Members can share the podcasts on their personal websites. Visit *MyOMS.org/Podcast*.

AAOMS Advantage

- **AAOMS Advantage** is proud to announce a new Partner Program with **Advancing Residents of OMS (AROMS)**. AROMS is a comprehensive online educational platform created exclusively for oral and maxillofacial surgery. Learn more at *AAOMSAdvantage.org*.

OMS Foundation Highlights

- **Mission Progress:** The Foundation continues advancing OMS through

donor engagement, philanthropy, and strategic program growth.

- **New Faculty Award:** Launching in 2026, the **LEAD Award** will support experienced OMS faculty pursuing advanced degrees or leadership roles.
- **Historic $2M Gift: Dr. & Mrs. Daniel J. Daley, Jr**. made one of the Foundation's largest gifts, prompting creation of the **Daniel J. Daley Millionaire Society.**
- **New Fellowship Award:** Beginning in 2026, the **Ramon L. Ruiz Endowed Fellowship** will support fellows focused on pediatric craniomaxillofacial surgery.
- **2025 OMS Foundation Strategic Plan:** Five key goals:
  - *Elevate awareness of the Foundation.*
  - *Cultivate future leaders.*
  - *Promote Foundation-funded research.*
  - *Strengthen donor engagement.*
  - *Modernize programs to meet evolving need.* ■

W. Frederick Stephens, DDS, FACD, FICD

Diplomate, American Board of Oral & Maxillofacial Surgery

AAOMS District VI Trustee

STAY CONNECTED

Follow CALAOMS

Association news, event and CE reminders, advocacy updates, and highlights from CALAOMS meetings.

Facebook
CALAOMSOfficial
SCAN TO FOLLOW

Instagram
@calaoms_official
SCAN TO FOLLOW

LinkedIn
California Association of Oral and Maxillofacial Surgeons
SCAN TO FOLLOW

2026 Year in Pictures

A look back at a year of advocacy, education and connection across the CALAOMS community.



Dr. Mahr Elder, Dr. Ken Wong, Dr. Vivian Jui and Dr. Nima Massoomi at the State Capitol.



Dr. George Maranon with Senator Laura Richards.



Dr. Nima Massoomi and Dr. Vivian Jui with Senator Roger Niello.

ADVOCACY DAY Members met with elected officials to talk about the extensive training oral and maxillofacial surgeons complete and their role in healthcare.



AAOMS HOUSE OF DELEGATES Back row, from left: Dr. Larry Moore, Dr. George Maranon, Dr. Sam Khoury and Dr. Dave Cummings. Front row, from left: Dr. Nima Massoomi, Dr. Don Liberty, Dr. Shama Currimbhoy, Dr. Lauren Odono, Dr. Vivian Jui, Dr. Ken Wong and Dr. Fred Stephens.



2026 JANUARY MEETING, SAN JOSE Dr. Edward Balasanian, Dr. George Maranon and Dr. Craig Thiede.







OBEAM AIRWAY TRAINING Members practice office-based emergency airway management in hands-on simulation sessions.







EXHIBITORS AND SPONSORS Thank you to the exhibitors and sponsors who supported CALAOMS programs throughout 2026.



IN-OFFICE TOUR Dr. Hooman Zarrinkelk, Angelica Cisneros and Melissa from Pro Tem Monique Limón's office, and Dr. Hessam Siavash.



CALIFORNIA CAREFORCE X-ray volunteers at the California CareForce Placer County Stand Down.



MEMBER MOMENTS Dr. Ken Wong and Dr. William Chung.

Artificial Intelligence in Oral and Maxillofacial Surgery (continued from page 3)

oversight. Implementing this innovative technology will involve a steep learning curve, but the effort will be well worth it.

Successful implementation begins with a specific need. Which tasks consume unnecessary staff time? Where do delays or repetitive work interfere with patient care? Choosing one workflow, establishing a baseline, and evaluating the results can make adoption more manageable. Practical areas to explore include documentation, staff support, imaging, billing, scheduling, and patient communication.

Let's examine how AI could support these workflows in a typical oral and maxillofacial surgery practice.

Documentation

Documentation offers a practical starting point for introducing AI into an OMS practice. When implemented effectively, AI tools can reduce the time spent writing notes and help produce more complete and organized documentation. An AI scribe can capture information during a consultation or use a surgeon's dictation to generate a clinical note, referral letter, or operative report. This can reduce repetitive writing and allow clinicians to devote more attention to patients.[2] However, AI generated documentation may omit critical details or introduce inaccurate information. The clinician must review documentation for omissions, inaccuracies, and other errors before it becomes part of the patient's record. Examples of AI documentation products include Kubo and Denti.AI Scribe. When selecting a system, practices should consider compatibility with existing software, ease of use, patient privacy, and consent requirements.

Imaging

AI can support imaging workflows by helping to identify anatomical structures, highlighting suspicious findings, and reducing the manual work involved in three-dimensional planning. Useful applications include third molar assessment, implant planning, evaluation of suspected pathology, and orthognathic surgery planning.

AI may assist with tasks such as tracing the mandibular canal, segmenting teeth and bone, and identifying anatomical landmarks. These capabilities can help surgeons review images and prepare treatment plans more efficiently.[3] Surgeons must verify AI findings and remain responsible for image interpretation and treatment decisions. Currently available AI imaging programs include Diagnocat, Relu Creator, coDiagnostiX, Blue Sky Plan, Invivo-Osteoid. These programs offer varying combinations of AI-assisted CBCT analysis, anatomical segmentation, scan alignment, and treatment planning support.

Surgery

AI and robotic applications in OMS are still developing. Current dental implant robotic systems include Yomi and Yomi S from Neocis, as well as Yakebot and Remebot in China. The FDA-approved Yomi platform provides physical guidance during implant surgery while the surgeon controls the handpiece. As of January 2024, more than two hundred robots have been installed across the United States and 40,000 implants had been placed using the technology.[4] These systems illustrate the progression from robotic assistance toward selected autonomous tasks rather than independent management of an entire surgical procedure.

Patient Communication

Patient communication often involves repetitive tasks, yet it remains essential to patient understanding, surgical recovery, and effective practice management. AI can support communication with patients and referring dentists by helping staff prepare clear, consistent information and manage routine inquiries.

For patient education, AI can draft understandable explanations of procedures, risks, alternatives, and recovery expectations. It can also help prepare procedure-specific materials to support the surgeon's informed consent discussion. Post-operatively, AI can help prepare routine instructions, follow-up messages, and flag patient concerns for staff review.

AI can simplify medical terminology and assist with written communications. AI can also assist with written translations, although translations used for consent or clinical instructions require qualified review. These tools should support direct communication between patients and the surgical team.

Administrative applications include answering routine telephone questions, collecting preliminary intake information, and routing calls. AI-enabled systems can also assist with appointment booking, sending reminders by email, text, or automated calls, optimizing schedules, and filling open appointment slots.[5] For referral management, AI can extract information from referrals, identify missing records, and draft updates to referring dentists. Staff oversight and protection of patient information remain essential throughout these workflows.

Revenue Cycle Management

AI can help reduce the administrative work involved in insurance processing,

VOLUME 28, Nº 2 · FALL 2026
COVER STORY

billing, and collections. Potential applications include assisting with eligibility checks, summarizing benefits, and preparing prior authorization requests. For billing and coding, AI can flag missing documentation or discrepancies for staff review and draft appeal letters.

AI can also help staff prioritize outstanding balances and draft payment reminders. Practice analytics tools can identify referral patterns and track case acceptance, cancellations, productivity, and financial performance. These insights can help practice leaders recognize inefficiencies and make more informed operational decisions. The value of these tools depends on accurate data, integration with existing systems, and staff review.

Marketing

AI can help OMS practices develop clear and consistent marketing materials, including website content, educational articles, social media posts, and newsletters for referring dentists. It can translate complex surgical topics into accessible explanations for prospective patients.

AI can draft responses to online reviews and analyze marketing performance to help practices understand which efforts generate interest and referrals. Review by surgeons and staff remains essential to ensure accuracy, protect patient privacy, and avoid misleading claims.[6] Currently available programs include Jasper for content creation, Canva Magic Studio for visual materials, and Birdeye for reputation management and patient outreach.

How Can AI Change Your Practice?

Today

AI programs can support OMS practices by assisting with documentation, imaging, patient communication, and administration. Certain applications can also help surgeons interpret findings and make treatment decisions. AI serves as an adjunct to clinical expertise, with human judgment, oversight, and responsibility remaining essential.

Of course, a successful practice can continue to provide excellent care today without adopting AI. The decision to introduce a tool should depend on whether it addresses a specific need and offers measurable benefits in efficiency, accuracy, or patient care.

> "AI serves as an adjunct to clinical expertise, with human judgment, oversight, and responsibility remaining essential."

Nevertheless, learning to effectively use novel technology takes time. Starting with a few practical applications allows surgeons and staff to build familiarity, understand limitations, and establish reliable workflows. The learning curve with novel technology can be steep, but *early adoption will make future implementation simpler and more effective*. This experience can prepare practices to evaluate more advanced tools as they emerge and adopt them as professional expectations and standards of care evolve.

In 10 Years

Over the next decade, AI may coordinate office workflows and provide more integrated support for clinical decision making. It could combine medical history, medications, imaging, and prior treatment into a concise patient assessment, helping surgeons personalize planning by providing treatment options and risk estimates.

Digital planning may become increasingly automated, with AI-generated anatomical models and proposed implant or orthognathic surgical plans for the surgeon's review and approval. During procedures, AI could support surgical navigation and provide alerts when instruments approach important anatomical structures. Administrative systems may also become more connected, coordinating referrals, scheduling, documentation, and insurance claims with less manual intervention.

As these capabilities develop, the surgeon's role will include critically evaluating AI recommendations, interpreting relevant findings, managing unexpected situations, and overseeing connected systems while retaining responsibility for patient care. The challenge will be turning a growing volume of information into useful clinical guidance without creating unnecessary distractions or excessive alerts.

These possibilities remain projections. Adoption will depend on demonstrated safety and effectiveness, reliable integration, cost, and appropriate regulatory approval. Although AI may become more deeply embedded in surgical planning, I believe widespread use of fully autonomous systems to perform oral and maxillofacial surgery is unlikely within the next 10 years.

In 25 Years

Over the next 25 years, AI could substantially change how oral and maxillofacial surgical care is planned and delivered. Patient-specific simulations may allow surgeons to compare surgical approaches and estimate optimal recovery trajectories prior to treatment. Robotic systems could perform selected procedural steps under surgeon supervision, while predictive tools may help identify patients at greater risk of complications and guide treatment adjustments to optimize outcomes.

These developments could also reshape staffing and training. As more routine tasks become automated, teams may need additional skills in managing technology, evaluating AI-generated information, and responding when systems fail or produce conflicting recommendations. Surgical training would need to incorporate these skills while preserving the clinical knowledge and operative abilities required to intervene safely.

The surgeon's responsibilities would continue to include establishing treatment goals, guiding informed consent discussions, supervising technology, and managing unexpected situations. *Maintaining patient trust and exercising sound clinical judgment would remain central to care*. The biggest changes would probably occur in routine diagnostics and administrative work rather than in the complete replacement of surgeons.

Predictions about the next 25 years are highly uncertain. *Technology is developing and evolving at the most rapid rate in human history*. Increasingly autonomous systems may become part of surgical practice during this period, but their adoption would depend on convincing evidence of safety and effectiveness, regulatory approval, affordability, and patient acceptance.[7] Whether fully autonomous oral and maxillofacial surgery will become routine within 25 years remains a possibility rather than a certainty.

In 50 Years

Looking 50 years ahead, increasingly autonomous surgery becomes more likely. AI-guided robotic systems may perform entire procedures with limited human intervention.[8] Such advances could arrive sooner; *the question is not "if" autonomous surgery will become mainstream, but "when?"*

In this future, oral and maxillofacial surgeons may increasingly direct and supervise robotic systems. The surgeon's role could shift toward complex decision making, oversight, and intervention when a procedure departs from its expected course. Training would need to preserve the operative skills required to take over safely while preparing surgeons to evaluate and manage these technologies.

> "Whatever form these advances take, their value should be measured by how well they improve patient care."

Greater AI and robotic autonomy would also raise questions about accountability, informed consent, patient trust, and access to care. The role of these technologies in practice would depend on demonstrated safety and effectiveness, as well as acceptance by patients, clinicians, and regulators.[9] AI and robotics will not replace surgeons, but they may make them more productive and change the profession in ways we can anticipate and others we cannot fully grasp. Whatever form these advances take, their value should be measured by how well they improve patient care.

Conclusion

Dr. Boudreau's question about accountability remains central. When an AI-generated suggestion appears convincing, we must assess whether it aligns with the patient's history, clinical examination, and imaging findings. We must continue to question AI conclusions, especially when they conflict with other findings, and remain responsible for the decisions that follow.

The opportunities for OMS are substantial, but our purpose should remain clear. We should adopt AI tools that improve patient care, reduce unnecessary work, and support sound clinical decisions. Their success should be measured by the quality of care we deliver and the time and attention we can return to our patients.

As evidence develops, specific AI applications will become integral to surgical practice. Thoughtful implementation today can help us prepare for the future while preserving the judgment, accountability, and human connection that define our profession. Although AI use in OMS practices is not currently the standard of care, *AI-driven technology will eventually become essential to surgery and be the new standard of care.* ■

References

1. Boudreau R. 'AI' in medicine - thoughts. The California Journal of Oral and Maxillofacial Surgery. 2026 Spring;28(1):37.
2. Van Buchem MM, Boosman H, Bauer MP, Kant IMJ, et al. The digital scribe in clinical practice: a scoping review and research agenda. NPJ Digit Med. 2021 Mar 26;4(1):57.
3. Nogueira-Reis F, Morgan N, Suryani IR, Tabchoury CPM, et al. Full virtual patient generated by artificial intelligence driven integrated segmentation of craniomaxillofacial structures from CBCT images. J Dent. 2024 Feb;141:104829.
4. Dahlberg, N. Neocis raises additional $20M in mission to revolutionize dental surgery through robotics. Refresh Miami. 2024 Jan 10. https://refreshmiami.com/news/neocis-raises-20m-to-continue-transforming-dental-surgery-with-robotics/
5. Preum SM, Munir S, Ma M, Yasar MS, et al. A review of cognitive assistants for healthcare: trends, prospects, and future directions. ACM Comput Surv. 2021;53(6):130:1-130:37.
6. FitzSimmons KA, Practice Management: Artificial Intelligence in Marketing-An Application for Dental Practices. Dent Clin North Am. 2025 Oct;69(4):541-554.

IMPLEMENTING AI

A deliberate approach, step by step

1 Start with a real need

Introduce a tool only when it addresses a specific need and offers measurable benefits in efficiency, accuracy or patient care.

2 Begin small

A few practical applications, like documentation, let surgeons and staff build familiarity, understand limitations and establish reliable workflows.

3 Review everything

Check AI-generated notes for omissions, inaccuracies and other errors before they become part of the patient's record.

4 Keep judgment human

Question AI conclusions, especially when they conflict with the history, exam or imaging. The surgeon stays responsible.

"We must continue to question AI conclusions, especially when they conflict with other findings, and remain responsible for the decisions that follow."

MAHR ELDER, DDS, MD

7. Jovy-Klein F, Stead S, Salge TO, Sander J, et al. Forecasting the future of smart hospitals: findings from a real-time Delphi study. BMC Health Serv Res. 2024 Nov 18;24(1):1421
8. Aleks Attanasio, Bruno Scaglioni, Elena De Momi, Paolo Fiorini, Pietro Valdastri. 2021. Autonomy in Surgical Robotics. Annual Review of Control, Robotics, and Autonomous Systems 4:651-679.
9. Yang G-Z, Cambias J, Cleary K, Daimler E, et al. Medical robotics—Regulatory, ethical, and legal considerations for increasing levels of autonomy. Sci Robot. 2017;2(4):eaam8638.

ANNOUNCEMENT

Medical Board of California Seeks OMS Expert Reviewers and Medical Consultants

The Medical Board of California's Expert Reviewer and Medical Consultant Programs are seeking licensed medical doctors with training and experience in oral and maxillofacial surgery to assist with quality-of-care complaints received by the Board.

This is a great opportunity to gain peer-review experience, weigh in on the standard of care, and support the integrity of the profession. The work is intermittent and online, and Medical Consultants and Experts help when they are available. The Board emails its pool of Medical Consultants and Experts when it has cases in their specialty area and asks anyone who is interested and available to reply. There is no penalty for declining an opportunity.

Learn more: Expert Reviewer Program | Medical Consultant Program



Artificial Intelligence in the OMS Practice: Three Pathways for Workflow Implementation

AUTHORS



Winston Doud, BSc(BioEng)



Peter Krakowiak, DMD, FRCD(C), FACD

In 2023, one of the coauthors wrote a small piece on emergence of Artificial Intelligence (AI) into our professional ecosystem. AI has experienced exponential growth since then. In healthcare, its primary application has been to reduce administrative burdens allowing providers and staff to dedicate more time to the interpersonal aspects of patient care. It will do a lot more than that in the coming decade.

In oral and maxillofacial surgery (OMS) practices, AI currently possesses the capability of managing various aspects of daily operations, including: clinical documentation, patient communication, and patient scheduling - without necessitating a complete overhaul of existing practice workflows or requiring advanced software. This article presents three primary implementation pathways, compares their respective strengths and limitations, and provides a practical example from experiences with implementation of AI at our multi-practice and provider private practice setting.

Pathway 1: Custom Built AI Platform - Our chosen path

A customized AI platform is tailored to the specific requirements and workflows of the practice. These platforms may be developed independently or by a vendor who configures an AI client to address each practice's unique needs. Unlike commercially available solutions, custom platforms can be designed to draft reports, letters, and notes in the surgeon's preferred format, route referrals directly into the practice's schedule, and manage billing and insurance operations. This approach is most appropriate for larger or small OMS practices with unique workflows and provide long-term plans for expanded automation.

Advantages

The AI client is constructed to align with the office's specific protocols and documentation formats. Features can be added or modified directly to optimize workflow efficiency. As operations evolve, the system can be gradually expanded to include additional functions. There really is no boundary where the system will stop its supportive role. Currently,

it is only involved in administrative and communication aspects of our practices. It essentially grows with you as you find more applications and workflow that can be serviced by automation.

Disadvantages

Although this pathway offers the greatest potential capabilities, it entails higher costs and slightly extended development timelines. Depending on the vendor and system complexity, a dedicated IT team may be necessary for ongoing updates and support. We have spent about 2 months to have a fully functional custom platform that has transformed our front office into an automated ecosystem with both machine learning and human interactions in key patient communications.

Pathway 2: Practice Management Software with Built-In AI

Numerous oral surgery practice management software programs now incorporate AI capabilities within their existing systems. Examples include DSN Atlas and Sensei Cloud. Depending on the platform, upgrading to an AI-powered version may provide features such as patient scheduling, voice-to-text transcription for clinical note-taking, and conversational AI linked to the software's database to address patient data queries. This pathway is appropriate for practices that are content with their current software and seek a straightforward introduction to AI.

Advantages

Since the AI features are designed for integration within the primary application, the upgrade process typically requires minimal setup time and limited workflow disruption. Office staff can continue utilizing a familiar interface, reducing the need for additional training. Furthermore, software updates, technical support, and system maintenance are typically managed by the vendor decreasing the practice's technical management responsibilities.

Disadvantages

Although technical maintenance and management held by the vendor is convenient, it removes interface customization or feature support which are essential to producing a system that is optimized to work with a practice's specific workflow. Additionally, AI features are typically offered as an additional cost with fees charged in addition to the base licensure. Relying on a single software provider may also increase the cost and complexity of transitioning to an alternative platform in the future. Typically, this requires the practice to keep their data off-site in a cloud system which may have downsides, as ownership or access to data can be disrupted.

Pathway 3: Standalone AI Subscription Service

Standalone AI platforms, such as Heidi Health and Vero Scribe, function as independent applications offering AI-powered practice management tools. The majority of these platforms offer documentation tools that convert clinical encounters into structured notes, subsequently, for use as referrals, letters, and reports, and an AI chatbot. This type of AI platform is most suitable for practices seeking a low-risk introduction to AI without replacing or modifying their existing software or patient communication workflows.

Advantages

Most subscription-based AI platforms offer free trials, enabling surgeons to assess capabilities prior to committing to a monthly fee requiring less upfront investment and minimal technical support. These platforms allow surgeons to incorporate specific AI functionalities without undertaking a substantial software upgrade.

Disadvantages

Although standalone AI platforms are generally straightforward to implement, their capabilities are restricted to the features provided by the vendor. Moreover, integration with existing management software may present challenges; while most platforms support direct integration with existing management systems, some may require manual transfer of documentation into the patient's chart. This additional step can disrupt workflow and increase the risk of documentation errors. Moreover, the capabilities of standalone AI platforms are currently limited primarily to charting notes and answering health-based queries, which means many of the possibilities that AI possesses such as managing billing, verifying insurance coverage, and managing chart data is not included as a feature.

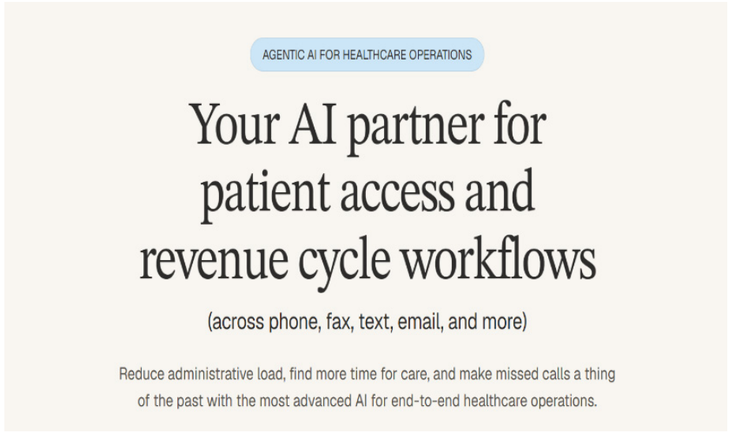

FIGURE 1: Confido Health's customizable AI platform was designed by us to streamline practice workflows.

Practical Implementation: Our Experience with Confido Health

At Lakeshore OMS, we recently began the implementation of a fully customizable AI client with Confido Health to reduce repetitive administrative tasks while maintaining our high standard of care and prompt patient communications. Confido Health is a New York-based company providing Agentic AI for many different specialties within healthcare - their most recent support of Agentic AI is ideal for the medium- to large-sized OMS practice, which gave us an opportunity to co-develop OMS specific tools and modules. More information on the full capabilities of tailored AI can be found on Confido's website: https://www.confido.health/.

With the assistance of Confido Health, we initially established an AI virtual assistant and database management ecosystem to meet the needs of our front office in approximately four weeks without needing to replace our existing practice management software or change hardware layout of a multilocation, multi-provider practice. Rather than adopting a pre-structured AI system, we collaborated with Confido Health to custom synthesize and train the AI to interact with patients, manage scheduling requests, and follow office workflows based on our already existing internal protocols. Confido provided us with a dedicated engineer to ensure the smooth implementation of the system, including on-site visits to better understand our needs and realities. That aspect was invaluable and prevented developing pathways that did not align with our needs and customary approaches to communications and patient experience.

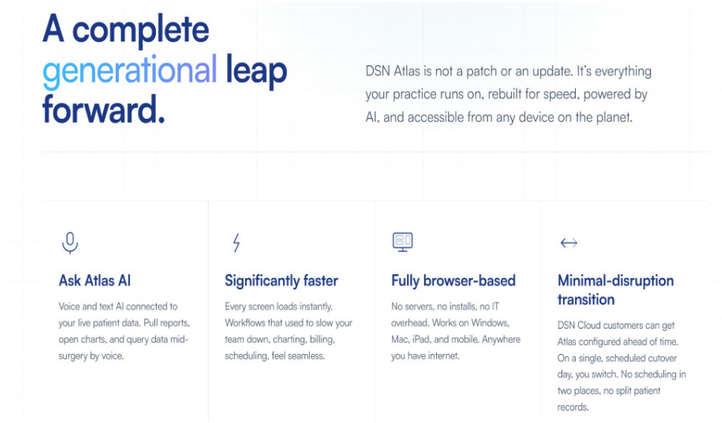

FIGURE 2: DSN Atlas is an upgrade to the current DSN application, featuring AI-powered tools to improve practice workflows.

Currently, the customized AI system handles all incoming calls, schedules patients for initial visits, makes outbound calls to confirm appointments, sends new patient forms, collects and verifies insurance copays, and contact referring offices to gather needed panoramic radiographs and referral slips. Incoming calls that require further assistance are screened and then forwarded to our office line where our staff is able to hear a quick summary of the call before taking over the line. Our staff can take on this call and devote more time to each patient as they are freed from most routine inquiries and/or non-material calls to the practice. The system operates 24 hours a day and can communicate in multiple languages. Since proof of concept has been established, we are embarking now on further integration into functions like monitoring KPI, detection of trends with insurance pay, and monitoring of individual staff performance, as well as practice systems optimizations. This is an important part to ensure that the office is running optimally and patient care is delivered with minimal waste of time and resources.

A key component of our successful AI integration has been intentionally limiting its initial capabilities to facilitate adjustments that enhance the AI's performance before introducing additional features. Beginning with clearly defined responsibilities enables careful monitoring of the AI's performance, allowing staff to evaluate and make necessary adjustments before expanding the system's role. Our team currently includes pre-dental bioengineering graduates, which has been helpful due to their increased ability to coordinate existing hardware as well as integrate new application software creativity. Having a capable, IT-savvy team member is key to this implementation pathway. We also have been able to have Confido engineers work on- and off-site to make the fine adjustments. This willingness to work on-site with us is unique for Confido and has been a big part of our success.

Although the integration of AI into Lakeshore OMS is still in its (what we foresee as) early phase, the staff have already seen a significant reduction in call volume following AI's implementation. Subsequently, this has translated to the practice devoting more time on the more interpersonal aspects of specialized patient care. Furthermore, the implementation of AI has enabled the consolidation of several previously independent services into a single platform. Our answering service, Doctible/new patient forms, and patient communication services have since been retired with their functions incorporated into the AI platform. This has streamlined our daily operation, reducing the reliance

VOLUME 28, Nº 2 · FALL 2026

OMS PAPERS

on multiple third-party services while improving the operational efficiency of the practice. Financially, consolidating all of these messaging and communication platforms under one AI umbrella that works and lives in our domain is a tremendous cost-savings and reduces our dependance on outside technology providers.

Following the successful implementation of the AI system's current capability ensures the next collection of capabilities the AI will possess. Planned functions include scheduling existing patients, verifying insurance benefits, managing consultation notes and reports, sending insurance claims, creating narrative letters for insurance appeals, following up on preauthorization, and following up on medical clearances. Beyond administrative tasks, the AI is expected to provide useful analytics on patient engagement, practice performance, identify when patients may require a follow-up regarding their treatment, provide referral suggestions, and manage inventory and hiring protocols.

AI will also bolster our online presence through search engine optimization (SEO), an interactive virtual assistant for website navigation, and provide general procedure information by utilizing an approved database of OMS videos and literature. These roles describe the next phase of AI integration extending its capabilities beyond basic administrative automation and towards a more comprehensive system.

We anticipate integration of AI workflows to use ambient listening in consultations and post-ops, to create encounter records, document consent discussions, and create real-time treatment plans, including breakdown of benefits and co-pays. It is expected that these will be active by the end of this year. The final, more clinically relevant implementation will be started in the new year with the addition of imaging diagnosis, medical work-up analysis, risk stratification, and specific suggestions

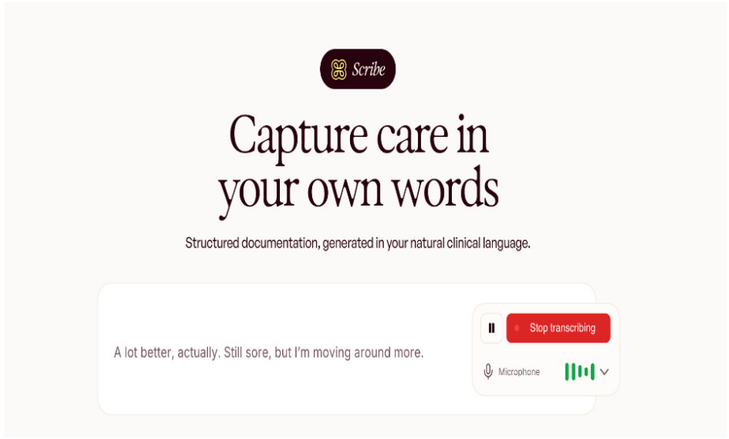

FIGURE 3: Heidi Scribe features speech to text dictation.

for evidence-based approaches to care of oral medicine, pathology, and surgical procedures. The databases involved will use myriads of external data to guide and identify areas where quality and appropriateness of our care can be improved. Of course, the final treatment choice will be a joint decision between patient and surgeon with maximum didactic consideration at hand coupled with our decades of clinical experience in OMS. Initially an entry level to front office operations is the starting point, and we are attempting to master the communication and data acquisition clerical workflow.

These capabilities are expected to offload a significant portion of administrative work from front office staff, allowing more time assisting patients. Our experience with Confido Health demonstrates that a customized AI platform can currently be launched rapidly and introduced iteratively to allow refinement of current features before integrating additional capabilities. We have certainly witnessed an exponential improvement in the AI's workflow in the first two weeks as it continuously adapts its output to become a seamless addition to the everyday routine of the practice. It certainly has passed the proof-of-concept stage and is entering the next echelon of its capability. Not surprisingly, it has exceeded the expected learning curve of most of our current and past human team members. However, in our setting, human interaction is still central to our caring and patient-centered healing ethos. We have not reduced our staff and feel that AI implementation is actually making our human team a stronger and more capable asset of the practice.

Finally, regardless of the chosen implementation pathway, patient privacy and clinical accuracy must remain paramount. All AI systems must comply with HIPAA and state privacy laws prior to implementation. Practices should thoroughly evaluate the vendor's security and data handling policies to ensure compliance before integration. Additionally, a thorough review of computer hardware and data storage solutions is a key component in ensuring the protection of sensitive patient data. Practices operating solely on cloud storage should carefully review their provided data redundancy, backup, and recovery solutions in the case of data loss. Local storage options provide practices with direct ownership and control of physical storage hardware, eliminating the need for cloud storage subscription fees and provides an additional layer of protection against data loss and ransomware attacks.

Conclusion

No single pathway is universally appropriate for all oral surgery practices. Successful implementation requires clearly defined practice needs and the selection of tailored adaptive technology that best complements the existing workflow. Whether through AI-integrated management software, a standalone subscription service, or a customized platform, AI can reduce administrative workloads and enhance operational efficiency, freeing time to strengthen relationships with patients and collaborative team members. AI is undoubtedly merging itself into every aspect of our daily lives - granted the efficiency and optimization capabilities it possesses. Its ability to work endlessly and with more precision to the specific needs of a practice makes it a powerful tool to employ. It is here now and will not be an optional part of our practice soon. This may be quite concerning to us from a variety of perspectives. Ultimately, the objective of AI is not to replace the capabilities of surgeons and staff, but to redirect time previously spent on clerical administrative tasks toward patient care, referring offices outreach, and make for better experiences for our patients through flawless adaptive organization and optimal around-the-clock multimedia communications. ■

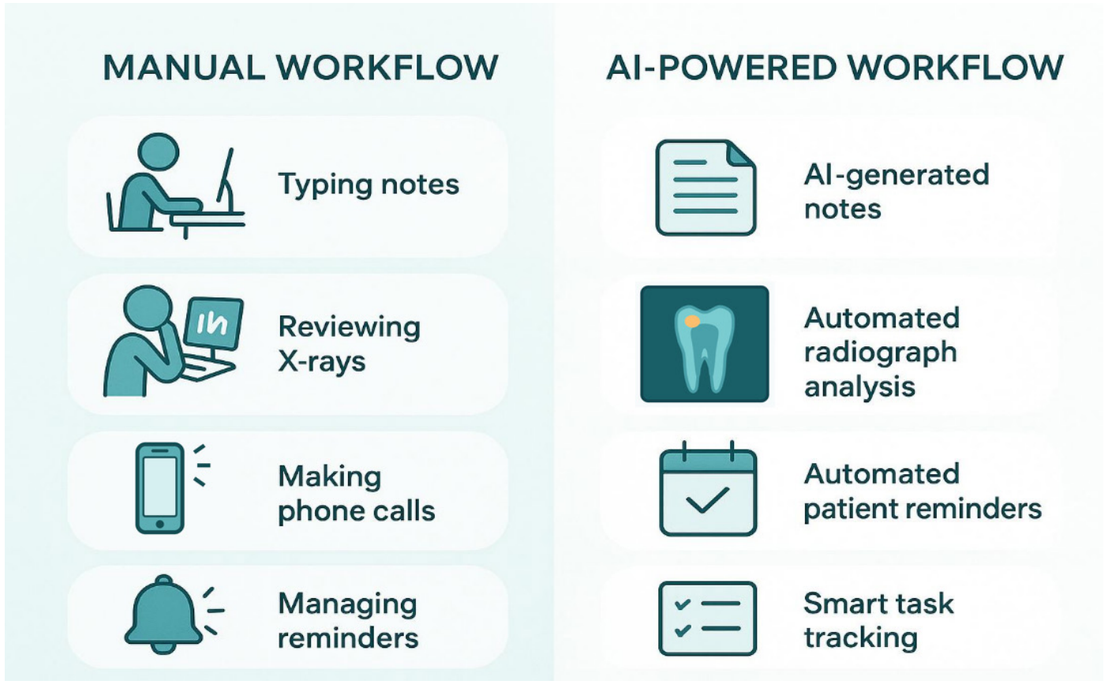

FIGURE 4: Manual vs. AI-powered workflows. Some AI capabilities shown, such as radiograph analysis, are potential applications rather than tools in use in every practice.

VOLUME 28, Nº 2 · FALL 2026

OMS PAPERS



Defect-Oriented Dual-Segment Acellular Dermal Matrix for Peri-Implant Contour and Keratinized Mucosal Augmentation: A Case Report

AUTHORS

Pietrangelo S. Vallebuona[a]
[a]Dental student, College of Dental Medicine, Western University of Health Sciences, Pomona, CA

Jeffrey A. Elo, DDS, MS, FACS[b]
[b]Division of oral and maxillofacial surgery, College of Dental Medicine, Western University of Health Sciences, Pomona, CA

Soft tissue architecture is a central component of implant therapy in the esthetic zone. A thin peri-implant phenotype or deficiency in facial volume can produce an unfavorable ridge contour, restorative show-through, and limitations in the development of a natural emergence profile. Facial tissue thickness is particularly relevant in the anterior maxilla, where small discrepancies in contour may influence the visual integration of an implant-supported restoration with the adjacent dentition.[1-3]

Autogenous connective tissue grafting remains a well-established reference approach for peri-implant soft tissue augmentation. However, donor-site morbidity, limited tissue availability, and increased surgical time have encouraged the use of extracellular matrix-based substitutes in selected situations. Acellular dermal matrix (ADM) provides a collagenous scaffold that can support host-cell migration, revascularization, and soft tissue integration when closely adapted and stabilized within an appropriate recipient bed.[4]

Peri-implant phenotype modification may be performed at different stages of implant therapy, including at second-stage surgery.[5] Tunneling procedures are particularly suited to esthetic sites because they preserve papillary architecture and maintain broad vascular coverage of the graft.[6] Contour deficiencies, however, are not necessarily uniform. A single implant site may demonstrate a localized coronal-apical deficiency together with a broader loss of facial convexity.

This case report describes a defect-oriented modification in which one ADM was divided into two independently designed and differently oriented segments. The vertical component was intended to support the coronal-apical tissue profile, while the horizontal component restored broader facial convexity. The technique also incorporated planned overlap, multi-point stabilization, and a limited area of open healing to address the keratinized mucosal dimension. The purpose of this report is to describe the clinical rationale, surgical sequence, and 6-month outcome of this combined approach.

Case Report

A 32-year-old male was referred by his prosthodontist for management of a persistent facial soft tissue deficiency associated with an implant replacing the maxillary right central incisor. The patient was healthy, a non-smoker, and had no relevant systemic conditions or medications.

The tooth was lost following a bicycle accident. Reconstruction of the site subsequently included bone grafting and implant placement. After osseointegration, a residual facial contour deficiency remained despite the previous hard tissue reconstruction, and the patient was referred for soft tissue management before definitive prosthodontic rehabilitation. The clinical sequence is summarized in Table 1.

Clinical examination demonstrated a thin periodontal phenotype and a marked facial concavity over the implant site (Figure 1). The peri-implant mucosa appeared clinically healthy, without suppuration or overt inflammation. The phenotype, spatial extent of the facial deficiency, and keratinized mucosal dimension were reassessed with a periodontal probe. Probe-based evaluation was used to complement visual assessment and provide a reproducible clinical reference for treatment planning.[7]

The principal treatment objective was to restore facial tissue volume and create a more natural peri-implant architecture while also increasing the available keratinized mucosal dimension. A medium-thickness ADM was selected to provide adequate initial volume while permitting passive adaptation of the facial tissue envelope.

Table 1. Clinical timeline

Key findings or intervention	Clinical stage
Bicycle accident with loss of the right central incisor.	Traumatic injury
Bone grafting followed by implant placement.	Site reconstruction
Residual facial soft tissue concavity and thin phenotype identified before definitive prosthodontic rehabilitation; reassessment performed with a periodontal probe.	Post-osseointegration referral
Papilla-preserving buccal tunnel; medium-thickness ADM divided into 5 x 12-mm vertical and 8 x 14-mm horizontal segments; controlled overlap; periosteal, independent horizontal, and healing-abutment-assisted stabilization; approximately 2 mm of controlled open healing.	Second-stage implant surgery
Suture removal; no graft loss or infection complication.	Approximately 1 week
Provisional restoration introduced for progressive emergence-profile conditioning.	After soft tissue maturation
Clinically stable facial contour with provisional restoration in place and approximately 2-mm increase in keratinized mucosal dimension; patient returned to the referring prosthodontist for continued temporary crown-guided mesial and distal papilla development and eventual definitive restorative treatment.	6 months

Expected biological remodeling was incorporated into graft planning. Published peri-implant volumetric data have demonstrated approximately 23% contraction of ADM between 1 and 12 months, with comparatively stable dimensions between 6 and 12 months.[8] This value was used as a planning reference rather than as a direct linear prediction of final graft thickness. The anticipated reduction in volume informed the initial distribution of the two segments and the planned area of overlap in the region requiring the greatest correction.

An autogenous connective tissue graft was discussed; however, the patient preferred to avoid a palatal donor site. ADM augmentation was therefore selected in conjunction with second-stage implant surgery.

Conservative access was performed over the implant cover screw while preserving the adjacent papillae (Figure 2). A partial thickness supraperiosteal tunnel was developed facially using microsurgical tunneling instruments (Figure 3). The recipient envelope was extended beyond the mucogingival junction and laterally beyond the adjacent line angles to permit



Figure 1. Preoperative clinical view of the maxillary right central incisor implant site demonstrating a thin periodontal phenotype and buccal soft tissue contour deficiency.

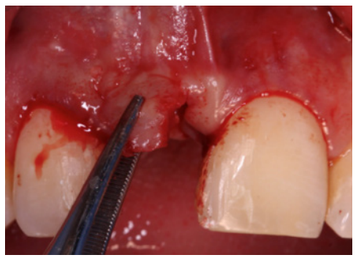

Figure 2. Conservative crestal access and buccal tunnel development during second-stage implant surgery, with preservation of the adjacent papillae.

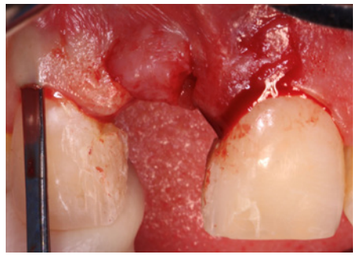

Figure 3. Prepared recipient tunnel and soft tissue release to allow passive placement of acellular dermal matrix without excessive marginal tension.

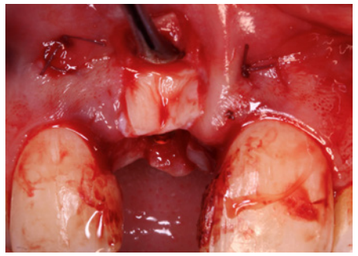

Figure 4. Intraoperative dual-segment ADM configuration. The vertical component was anchored apically to the periosteum, while the horizontal component was independently stabilized across the facial deficiency. The coronal portion of the vertical segment was positioned beneath the horizontal segment, creating a controlled region of overlap. The healing abutment assisted coronal stabilization of the vertical component through the preformed perforation.

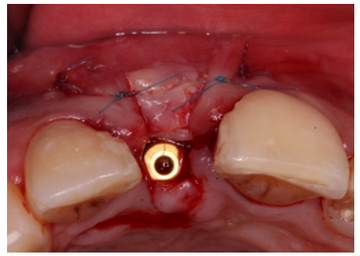

Figure 5. Stabilized ADM with intentional partial exposure of the matrix. Approximately 2 mm of separation was maintained between the facial wound margins to permit secondary epithelialization while the submerged portion provided facial volumetric support. Restorative loading was delayed to reduce soft tissue pressure during early healing.

passive graft positioning. A localized frenal release was performed to reduce tension on the facial tissue envelope.

The ADM was prepared before hydration. While dry, the matrix was trimmed according to the clinical defect analysis into two patient-specific components. The vertical segment measured approximately 5 x 12 mm and the horizontal segment approximately 8 x 14 mm. A minimal perforation was created in the coronal portion of the vertical segment with a rubber dam punch. Trimming and punching before hydration facilitated controlled handling and creation of a small, defined opening. Both components were subsequently hydrated according to the manufacturer's instructions.

The vertical segment was introduced first. Its apical portion was positioned along the coronal-apical component of the facial deficiency and anchored directly to the underlying periosteum with a 5-0 resorbable polyglycolic acid suture. This segment was intended to restore the facial prominence normally associated with the cervical and radicular portion of a natural central incisor.

The 8 x 14-mm horizontal segment was then positioned across the broader facial deficiency and independently stabilized. After fixation of the horizontal component, the coronal portion of the vertical matrix was adapted beneath it, creating a controlled region of overlap over the facial aspect of the implant (Figure 4). Double-layer ADM applications have previously been described.[9] In the present case, however, the two components were independently dimensioned and oriented according to separate anatomical components of the defect rather than simply superimposed to create uniform thickness.

Following graft positioning, the healing abutment was connected through the preformed perforation in the vertical matrix. The vertical component was therefore stabilized apically through periosteal anchorage and coronally with assistance from the healing abutment, while the horizontal component remained independently secured facially. An early implant-specific technique from the Loma Linda University group similarly used an implant-supported component to stabilize an acellular dermal allograft during second-stage surgery, providing precedent for implant-assisted graft stabilization.[10]

Complete primary approximation of the facial wound margins was intentionally avoided. Approximately 2 mm of separation was maintained, leaving a controlled portion of the stabilized ADM exposed for open healing and secondary epithelialization (Figure 5). The submerged portion of the graft provided volumetric support, whereas the exposed portion served as a scaffold for expansion of the keratinized mucosal dimension. Human histologic observations support cellular repopulation and epithelialization of ADM,[11] and clinical reports have described increases in keratinized or attached tissue after open-healing applications, including around dental implants.[12,13] The remaining wound margins were stabilized with 6-0 nylon interrupted sutures.

Immediate provisionalization was intentionally avoided to minimize pressure and shear forces during early graft incorporation. Postoperative instructions included avoidance of mechanical trauma to the surgical site and careful plaque control. Sutures were removed approximately 1 week after surgery.

Healing was uneventful, without graft loss, suppuration, infection, or clinically significant peri-implant inflammation. The intentionally exposed portion of the matrix demonstrated progressive epithelialization. Clinical reassessment with the periodontal probe demonstrated an approximately 2-mm increase in the keratinized mucosal dimension compared with the preoperative condition.

Following maturation of the augmented tissues, a provisional restoration was introduced to begin development of the peri-implant emergence profile.

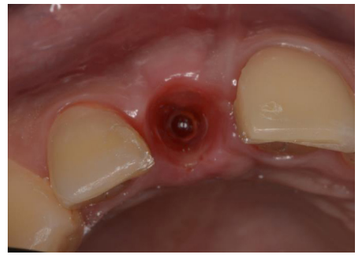

Figure 6. Postoperative clinical view demonstrating qualitative improvement in buccal soft tissue convexity compared with the preoperative contour.



Figure 7. Six-month follow-up demonstrating peri-implant mucosal maturation before transfer back to the referring dentist for continued development of mesial and distal papilla with custom temporary until ready for final crown.

This represented a complementary second phase of treatment: surgery first established the available tissue volume, while the provisional restoration subsequently conditioned that volume to refine the cervical architecture.[14] Serial clinical photographs demonstrated reduction of the original facial concavity and development of a more convex peri-implant profile (Figure 6).

At the 6-month evaluation, the augmented facial architecture remained clinically stable with healthy peri-implant tissues and the provisional restoration in place (Figure 7). The patient was subsequently returned to the referring prosthodontist for continued mesial and distal papilla development through the use of customized temporary crown interproximal contact points, and the patient is pending final crown restoration once the papilla achieve optimal height.

Discussion

This case describes a defect-oriented dual-segment ADM configuration designed to manage a multidimensional peri-implant soft tissue deficiency during second-stage implant surgery. Its distinguishing feature was not simply the use of two ADM layers, but the use of two independently dimensioned and differently oriented components with separate anatomical objectives and stabilization strategies.

The configuration was based on the three-dimensional morphology of the deficiency. The vertical component supported the coronal-apical profile and was intended to recreate the facial prominence normally associated with the cervical and radicular portion of a natural central incisor. The larger horizontal component addressed the broader loss of facial ridge convexity. This approach can therefore be considered a form of site-specific volumetric augmentation, in which graft volume is distributed according to the spatial characteristics of the defect rather than uniformly across the recipient site.

This concept is particularly relevant after traumatic anterior tooth loss. Successful hard tissue reconstruction and implant osseointegration do not necessarily reproduce the original soft tissue architecture. Residual deficiencies may become most evident at the restorative phase, when even a well-positioned implant can appear deficient because of loss of facial contour. Contemporary peri-implant phenotype literature and long-term anterior implant data support the importance of adequate facial soft tissue thickness for esthetic integration and tissue stability.[1-3,5]

Expected biological remodeling represented an additional component of the treatment design. Published volumetric data indicates that a meaningful portion of the initial ADM augmentation is lost during maturation.[8] In this case, the controlled overlap between the vertical and horizontal segments was positioned where both root prominence and facial convexity required reconstruction. The overlap was not interpreted as a mathematically predictable doubling of tissue thickness. Instead, expected contraction was used as a planning reference to justify controlled initial over-augmentation while preserving passive adaptation of the tissue envelope.

The dual-segment concept also differs from previously described double-layer ADM approaches. Mahn[9] reported a modified tunnel technique using double-layer ADM, establishing precedent for layered use of the material. The present configuration extends that concept by assigning each segment a distinct spatial role and fixation strategy. The vertical segment was anchored to the periosteum apically and supported coronally by the healing abutment, while the horizontal segment was independently fixed across the facial deficiency. This multi-point stabilization was intended to reduce micromotion and maintain the planned relationship between the two segments during early incorporation.

The use of the healing abutment as part of graft stabilization also has historical precedent. Proussaefs et al[10] described an early Loma Linda University approach in which an implant-supported component helped stabilize an acellular dermal allograft during second-stage surgery to increase peri-implant keratinized tissue. In the present case, a small perforation prepared before hydration allowed the healing abutment to pass through the coronal portion of the vertical segment with minimal disruption of the graft, providing mechanical support without requiring an additional external stent.

Intentional partial exposure of the matrix added a second objective to the procedure. Histologic evidence has demonstrated host-cell migration, vascularization, and progressive epithelialization of ADM used for gingival augmentation.[11] Clinical

VOLUME 28, Nº 2 · FALL 2026

OMS PAPERS

reports have also documented successful open healing and increases in keratinized tissue when ADM is securely stabilized, including at implant sites.[12,13] In this patient, maintaining approximately 2 mm of separation between the wound margins allowed the same intervention to address two components of the peri-implant phenotype: submerged, direction-specific augmentation for facial volume and controlled open healing for expansion of the keratinized mucosal dimension.

The tunneling approach complemented this strategy by preserving the papillae and maintaining vascular coverage over the submerged portions of the ADM.[6] The combination of a vascular recipient bed, close graft adaptation, controlled fixation, and passive tissue positioning was intended to create a favorable environment for graft incorporation while limiting disruption of the adjacent esthetic architecture.

The surgical and restorative phases were also conceived as complementary. Rather than attempting to compensate for a deficient facial tissue envelope through excessive cervical restorative bulk, tissue volume was first created surgically and allowed to mature before prosthetic conditioning. Provisional restorations can then progressively shape the peri-implant emergence profile within an adequate soft tissue envelope.[14] This staged sequence is consistent with surgical-prosthetic approaches described for esthetic peri-implant soft tissue deficiencies.[15]

This principle may be particularly relevant in patients with a high smile line, where the facial mucosa, gingival margin, and cervical portion of the restoration are readily visible. Small deficiencies in facial volume may create shadowing, asymmetry, or an abrupt transition between an implant-supported crown and the adjacent natural teeth. Strategically distributing soft tissue volume may provide the restorative clinician with a more favorable framework for a natural emergence profile and a visually seamless transition between restoration and surrounding tissues.

The exact 5 x 12-mm and 8 x 14-mm dimensions used in this case should not be interpreted as standardized measurements. Matrix thickness, segment dimensions, orientation, overlap, and fixation should be adapted to the morphology of the individual deficiency and the capacity of the recipient tissue envelope.

> "The surgical and restorative phases were also conceived as complementary."

The principal limitations are the single-case design and absence of quantitative three-dimensional volumetric analysis or ultrasound-based tissue-thickness measurements. The observed contour changes are therefore presented as clinical and photographic findings. Longer follow-up and prospective quantitative evaluation will be required to determine the reproducibility, dimensional stability, and comparative benefit of this configuration.

Conclusion

A defect-oriented dual-segment ADM configuration was used during second-stage implant surgery to address multiple components of an anterior peri-implant soft tissue deficiency following traumatic tooth loss and previous hard tissue reconstruction. A vertically oriented ADM segment supported the coronal-apical tissue profile, while a larger horizontal segment restored broader facial convexity. Controlled overlap concentrated additional initial volume in the region requiring the greatest correction, and periosteal anchorage, independent horizontal fixation, and healing-abutment-assisted coronal stabilization maintained the planned configuration.

Intentional partial exposure of the stabilized ADM permitted secondary epithelialization and was associated with an approximately 2-mm increase in keratinized mucosa. At 6 months, the augmented facial architecture remained clinically stable with the provisional restoration in place. This approach integrates defect-specific volumetric planning, multi-point graft stabilization, controlled open healing, and staged prosthetic conditioning within a single second-stage surgical procedure. ■

References

1. Wang ICI, Barootchi S, Tavelli L, Wang HL. The peri-implant phenotype and implant esthetic complications. J Esthet Restor Dent. 2021;33(1):212-23.
2. Rungcharassaeng K, Kan JYK, Yoshino S, Morimoto T, Zimmerman G. Immediate implant placement and provisionalization with and without a connective tissue graft: an analysis of facial gingival tissue thickness. Int J Periodontics Restorative Dent. 2012;32(6):657-63.
3. Kan JYK, Yin S, Rungcharassaeng K, Zucchelli G, Urban I, Lozada J. Facial implant gingival level and thickness changes following maxillary anterior immediate tooth replacement with scarf-connective tissue graft: a 4-13-year retrospective study. J Esthet Restor Dent. 2023;35(1):138-47.
4. Tavelli L, McGuire MK, Zucchelli G, Rasperini G, Feinberg SE, Wang HL, et al. Extracellular matrix-based scaffolding technologies for periodontal and peri-implant soft tissue regeneration. J Periodontol. 2020;91(1):17-25.
5. Tavelli L, Barootchi S, Avila-Ortiz G, Urban IA, Giannobile WV, Wang HL. Peri-implant soft tissue phenotype modification and its impact on peri-implant health: a systematic review and network meta-analysis. J Periodontol. 2021;92(1):21-44.
6. Zuhr O, Rebele SF, Cheung SL, Hürzeler MB. Surgery without papilla incision: tunneling flap procedures in plastic periodontal and implant surgery. Periodontol 2000. 2018;77(1):123-49.
7. Kan JYK, Morimoto T, Rungcharassaeng K, Roe P, Smith DH. Gingival biotype assessment in the esthetic zone: visual versus direct measurement. Int J Periodontics Restorative Dent. 2010;30(3):237-43.
8. Papi P, Penna D, Di Murro B, Pompa G. Clinical and volumetric analysis of peri-implant soft tissue augmentation using an acellular dermal matrix: a prospective cohort study. J Periodontol. 2021;92(6):803-13.
9. Mahn DH. Modified tunnel technique and double-layer acellular dermal matrix to treat multiple teeth and implant: 3.5-year results. Compend Contin Educ Dent. 2020;41(9):e1-e4.
10. Proussaefs P, Lozada J, Kleinman A. The "Loma Linda stent": a screw-retained resin stent. J Oral Implantol. 2003;29(1):19-23.
11. Scarano A, Barros RR, Iezzi G, Piattelli A, Novaes AB Jr. Acellular dermal matrix graft for gingival augmentation: a preliminary clinical, histologic, and ultrastructural evaluation. J Periodontol. 2009;80(2):253-9.
12. Shi Y, Segelnick SL, El Chaar ES. A modified technique of tacking acellular dermal matrix to increase keratinized mucosa around dental implants as an alternative to a free gingival graft: a case report. Clin Adv Periodontics. 2020;10(4):175-80.
13. Wei PC, Laurell L, Geivelis M, Lingen MW. Acellular dermal matrix allografts to achieve increased attached gingiva. Part 1. A clinical study. J Periodontol. 2000;71(8):1297-305.
14. Wittneben JG, Buser D, Belser UC, Brägger U. Peri-implant soft tissue conditioning with provisional restorations in the esthetic zone: the dynamic compression technique. Int J Periodontics Restorative Dent. 2013;33(4):447-55.
15. Zucchelli G, Mazzotti C, Mounssif I, Marzadori M, Stefanini M. Esthetic treatment of peri-implant soft tissue defects: a case report of a modified surgical-prosthetic approach. Int J Periodontics Restorative Dent. 2013;33(3):327-35.

THE TECHNIQUE

One graft, two segments



VERTICAL SEGMENT

5 × 12 mm

Anchored apically to the periosteum along the coronal-apical part of the deficiency.



HORIZONTAL SEGMENT

8 × 14 mm

Positioned across the broader facial deficiency and stabilized independently.



WHERE THEY MEET

Controlled overlap

Over the facial aspect of the implant. The healing abutment passes through a small perforation in the vertical segment.

PLACEMENT ORDER

1. Vertical segment first
2. Horizontal segment next
3. Overlap set; abutment through the vertical segment
4. ~2 mm left to heal open

~2 mm Increase in keratinized mucosa at 6 months, with a clinically stable facial contour.

Shapes are schematic, not to scale. Dimensions are those used in this case, not standardized measurements.

VOLUME 28, Nº 2 · FALL 2026
PRACTICE MANAGEMENT



Asset Protection for the Oral and Maxillofacial Surgeon

AUTHOR



Solomon Poyourow, DDS, MD, MPH

Asset protection is lawful, advance planning that makes a surgeon an unattractive target and gives a plaintiff every reason to settle within insurance limits. It is not secrecy, it is not tax evasion, and it is not something that can be assembled after a bad outcome.

Why oral and maxillofacial surgeons are targets

Oral and maxillofacial surgeons carry a risk profile that general dentists do not. We administer deep sedation and general anesthesia in an office setting, operate in the proximity of important nerves, manage facial trauma and infections, and treat medically frail patients. A single anesthetic death or permanent nerve injury can produce a demand that exceeds a $1 million policy limit.

California's MICRA protection has also weakened. Under AB 35, the cap on noneconomic damages rose in 2023 from $250,000 to $350,000 in injury cases and $500,000 in death cases. It climbs each year until it reaches $750,000 and $1 million, respectively, in 2033. Economic damages, such as a young patient's lifetime lost earnings and future care, have never been capped.

Malpractice is only one exposure. The claims that most often pierce a surgeon's coverage arise elsewhere:

- A serious auto accident, especially one involving a teenage driver on the family policy.
- Employment claims: harassment, wrongful termination, wage-and-hour and PAGA actions.
- Injuries at rental property or at the building that houses the practice.
- Personal guarantees on leases, equipment loans, and practice acquisition debt.
- Partnership disputes and vicarious liability for associates and staff.
- Claims that insurers exclude outright, such as intentional acts, sexual misconduct allegations, and punitive damages.

A plaintiff's attorney working on contingency asks one question *before investing in a case beyond policy limits*: Can I collect? Good planning makes the honest answer: "not easily."

Rule One: the plan must exist before the event

Every asset protection tool in this article works only if it is in place before a claim arises. Planning done after an adverse event is worthless.

California's Uniform Voidable Transactions Act (Civil Code section 3439 et seq.) lets a creditor unwind any transfer made with intent to hinder, delay, or defraud a creditor. It also reaches transfers made for less than fair value by someone who was insolvent or became insolvent as a result. The creditor does not need a judgment, or even a filed lawsuit, at the time of the transfer. A patient with a known bad outcome is already a creditor for these purposes.

Courts infer intent from "badges of fraud" listed in the statute. The most damaging are:

- The transfer followed a threatened or pending claim.
- The transfer went to a spouse, child, or entity the debtor controls.
- The debtor kept possession or control of the asset.
- The transfer was concealed.
- The debtor received little or nothing in return.
- The transfer left the debtor with too little to pay foreseeable debts.

The creditor has four years from the transfer to sue, or one year from when the transfer was or could reasonably have been discovered, with an outer limit of seven years. In bankruptcy, the trustee can reach back ten years for transfers to self-settled trusts made with intent to defraud (11 U.S.C. section 548(e)).

Late planning also creates new problems. A fraudulent conveyance is a crime in California (Penal Code section 531). It can cost the debtor a bankruptcy discharge. It exposes the family members, advisers, and entities that received the assets to their own liability. It also destroys the surgeon's credibility in front of the same judge who will decide every later dispute.

The practical lesson is to plan when the sky is clear. A surgeon who funds a structure while solvent, with no known claims, for documented estate planning, retirement, and business reasons, has a plan that will hold. Good counsel will document solvency at the time of each transfer, often with a signed solvency declaration and a current balance sheet.

Insurance: the first layer, and why it is not enough

Insurance is the foundation of every plan because it pays for the defense as well as the judgment. No trust or LLC hires a lawyer for you.

Professional liability. Review limits against today's MICRA caps, not the 1975 figures. Know whether the policy is claims-made or occurrence, whether defense costs erode the limit, whether you hold a consent-to-settle right, and what tail coverage will cost at retirement or a practice sale. Tail coverage can be estimated around three times the last year's premium. It is worth considering increasing from the standard $1 million/$3 million policy to $2 million/$5-6 million.

> "The practical lesson is to plan when the sky is clear."

Personal umbrella. An umbrella policy is the cheapest protection available. Limits of $5 million to $10 million often cost a few thousand dollars a year, and the carrier supplies defense counsel. Every surgeon should carry one sized to net worth, with underlying auto and homeowner limits set to the umbrella's attachment point so there is no gap. It is essential to make sure umbrella, auto, and homeowner's are coordinated, as umbrella generally has very specific requirements on the underlying auto and homeowner's policies.

Personal umbrella excludes professional services and business activities, so it will not respond to a malpractice or employment claim. It excludes intentional acts, and California law bars insurance for punitive damages. Rental properties are often covered only if scheduled. The practice would need its own commercial umbrella, employment practices liability (EPLI), and cyber coverage, if those policies are desired.

Coverage can disappear when you need it most. This is the point surgeons most often miss. Insurance is a contract renewed one year at a time, and the carrier's underwriters see every claim. Once a significant claim is open:

- The carrier may defend under a reservation of rights, then deny coverage if facts fall within an exclusion.
- The carrier may seek to rescind the policy for a misstatement on the application.
- The policy may be non-renewed at the next anniversary or renewed at a far higher premium with new exclusions.
- No carrier will sell new or higher limits for a loss that has already occurred.
- A second claim during the same period may find the aggregate limit already depleted.
- A claims-made policy that lapses without tail coverage leaves prior acts uninsured.

In other words, a surgeon who relies on insurance alone has protection that is strongest before the first claim and weakest after it. A verdict above limits, a declined claim, or a non-renewal leaves personal assets as the only source of recovery. That is the gap the rest of this article addresses.

Statutory exemptions and California private retirement plans

The strongest protection is the kind a legislature hands you. Exempt assets need no trust and no entity, and moving non-exempt cash into exempt form is treated far more leniently than hiding it.

ERISA-qualified plans. A 401(k), profit-sharing, defined benefit, or cash

VOLUME 28, Nº 2 · FALL 2026
PRACTICE MANAGEMENT

balance plan covering at least one non-owner employee is protected by federal law without a dollar limit. A Solo 401(k) is not an ERISA plan and is treated like an IRA and has weak protection. For a surgeon in peak earning years, a cash balance plan stacked on a 401(k) can shelter several hundred thousand dollars a year with a tax deduction as well.

IRAs. California is weak here. Under Code of Civil Procedure section 704.115(e), an IRA is exempt only to the extent a judge finds it necessary for the support of the debtor and dependents in retirement. A 55-year-old surgeon with high earning capacity may be told that little is "necessary." Think carefully before rolling a protected qualified plan into an IRA, and do not count on an inherited IRA being protected at all.

California private retirement plans (PRP). A California PRP is unique to California and one of the best asset protection strategies for California residents. Section 704.115 separately exempts, in full, assets held in a "private retirement plan" established by a private employer, including the surgeon's own professional corporation. The plan need not be tax-qualified, so contribution limits do not apply, and it can hold after-tax savings, brokerage accounts, and other investments. Distributions keep their exempt character if they can be traced.

A private retirement plan (PRP) is a legitimate and powerful California tool, and it is also one of the most oversold. Courts apply a consistent test: the plan must be designed and used *principally for retirement purposes*. Cases such as *In re Bloom*, *In re Rucker*, *Yaesu Electronics v. Tamura*, and *Schwartzman v. Wilshinsky* show what wins and what loses:

- A written plan, an independent or at least formal administrator, and contributions tied to a real retirement funding calculation support the exemption.
- Funding the plan after a claim arises, moving nearly all net worth into it, or contributing assets that have nothing to do with retirement undermines it.
- Using the plan as a checking account, taking undocumented loans, or withdrawing funds for current lifestyle can forfeit it.

"A private retirement plan (PRP) is a legitimate and powerful California tool, and it is also one of the most oversold."

- A PRP gives no tax deduction and no tax deferral; it is a creditor exemption only.

Be skeptical of anyone selling a PRP as a box into which the house, the practice, and the vacation property can all be placed. A well-run PRP holding a reasonable, actuarially supported share of liquid savings is defensible. An overstuffed one invites a judge to disregard the whole plan.

Homestead. Since 2021, California protects home equity equal to the county median sale price, with a floor of $300,000 and a ceiling of $600,000, both indexed for inflation (CCP section 704.730). In coastal counties, that still leaves most of a surgeon's equity exposed.

Other exemptions are narrow. Life insurance cash value and annuities receive only token protection in California, unlike Florida or Texas. Disability benefits are exempt to the extent needed for support. Seventy-five percent of wages are generally shielded from garnishment, but a surgeon's corporate distributions may not qualify as wages.

Entities: the practice corporation and one LLC per property

The professional corporation. California does not allow a dental or surgical practice to operate as an LLC, so the practice entity is a professional dental corporation. It will not shield a surgeon from personal malpractice. It does shield personal assets from the corporation's other liabilities: a partner's or associate's malpractice, employment claims, the premises lease, and vendor contracts that were not personally guaranteed.

Keep the practice entity lean. Valuable assets should not sit inside the entity most likely to be sued. The building belongs in a separate LLC that leases it to the practice at fair rent under a written lease. Some surgeons also hold major equipment in a separate leasing entity. Excess cash should be distributed and moved into protected form, not left to accumulate in the corporate account.

Why LLCs suit real estate. An LLC protects in two directions, and the distinction matters.

Inside-out risk is liability that arises from the asset itself: a tenant's fall, a fire, a mold claim, an environmental problem. If the property is held in a properly run LLC, the claimant's recovery is limited to the insurance and the equity inside that LLC. The surgeon's home, savings, and other properties are not reachable.

Outside-in risk is liability that arises from the owner's life, such as a malpractice verdict above limits or an auto accident. A creditor with a judgment against an LLC member cannot simply seize the LLC's property. The statutory remedy is a charging order, a lien on distributions if and when the manager makes them (Corporations Code section 17705.03). The creditor gets no vote, no management rights, and no right to force a sale of the property. That protection is weakest when the LLC has a single member, because a court has no other owner to protect and may let the creditor reach the property. The fix is a real second member: an irrevocable trust for one's children holding a meaningful minority interest in the LLC or its parent holding company.

One property, one LLC. If three rentals sit in one LLC, a lawsuit arising from one puts the equity of all three at stake. Separate LLCs keep each property's inside-out risk in its own box. This costs California's $800 minimum franchise tax per entity each year, plus a gross receipts fee for larger LLCs. For meaningful equity, it is inexpensive insurance.

The limits of LLC protection in California. An honest adviser will explain these as well:

- California lets a court order foreclosure and sale of the debtor's membership interest when distributions will not pay the judgment in a reasonable time. The buyer receives economic rights only, but the charging order is not the impenetrable wall some promoters describe.
- Single-member LLCs are the weakest form. Courts in several states and in bankruptcy have let creditors reach the assets of a single-member LLC, reasoning that there are no other members to protect.
- California recognizes outside reverse veil piercing against LLCs. In *Curci Investments, LLC v. Baldwin* (2017), the Court of Appeal allowed a creditor to pursue an LLC's assets directly where the debtor used it as an alter ego.
- A Nevada, Wyoming, or Delaware LLC does not change the result. An LLC that owns California real estate must register here and pay the same tax, and a California court will apply California law to California land and a California debtor.
- Formalities matter. Commingled funds, personal expenses paid from the LLC account, no operating agreement, no lease, and no insurance are the facts that lead courts to disregard the entity.

A stronger design was mentioned earlier: a multi-member LLC with a real second member, such as an irrevocable trust for children. The operating agreement should give the manager discretion over distributions and restrict transfers. Each LLC should carry its own liability policy.

"An asset you no longer own cannot be taken from you."

Before deeding property into an LLC, check four things. Confirm the property tax reassessment exclusion for transfers that keep proportional ownership identical. Review the lender's due-on-sale clause. Obtain a title insurance endorsement. Add the LLC as named insured on the property and umbrella policies.

Three things that do not protect you

Your living trust. A revocable trust avoids probate and nothing more. Because you can revoke it, your creditors can reach everything in it (Probate Code section 18200).

Your spouse's name. California is a community property state. Community property is liable for a debt incurred by either spouse during marriage, no matter whose name is on title (Family Code section 910). Retitling the house to a non-physician spouse accomplishes nothing unless the spouses sign a formal transmutation agreement converting it to separate property. A transmutation is itself a transfer subject to the voidable transactions law, and it has permanent consequences in a divorce. California also has no tenancy by the entirety.

A trust you create for yourself. Under Probate Code section 15304, if you are a beneficiary of a trust you funded, your creditors can reach the maximum amount the trustee could distribute to you. A spendthrift clause does not change that. This single rule drives most of what follows: in California, trusts protect assets you have given to *someone else*.

Irrevocable trusts that work in California

An asset you no longer own cannot be taken from you. A completed gift to a properly drafted irrevocable trust for a spouse, children, or charity, made while solvent, is beyond the reach of your later creditors. A spendthrift clause and an independent trustee with discretion over distributions then protect it from the beneficiaries' creditors as well.

These trusts are usually built for estate tax reasons, and that helps. A transfer with a documented tax and family purpose is far harder to attack than one whose only purpose is creditor avoidance. The federal estate and gift tax exemption is $15 million per person in 2026 and indexed after that. Many surgeons will not owe federal estate tax, so today the asset protection benefit is often the main reason to use these tools.

Spousal lifetime access trust (SLAT)

One spouse gives separate property to an irrevocable trust for the other spouse and, usually, the children. The assets leave the donor's estate and the reach of the donor's creditors. The family keeps indirect access because the trustee can distribute to the beneficiary spouse. For a surgeon, the natural design has the surgeon as donor and the lower-risk spouse as beneficiary.

The pitfalls are specific:

VOLUME 28, Nº 2 · FALL 2026
PRACTICE MANAGEMENT

- **Community property must be transmuted first.** If the trust is funded with community property, the beneficiary spouse is treated as a contributor to a trust for their own benefit. That undermines both the tax result and the creditor protection.
- **Divorce.** The donor's indirect access ends, and the donor may keep paying income tax on trust income that benefits a former spouse. Drafting options exist but must be chosen in advance.
- **Death of the beneficiary spouse.** Access ends unless the trust was drafted with a backstop.
- **Reciprocal trusts.** If each spouse creates a near-identical SLAT for the other, the IRS and creditors can "uncross" them and treat each spouse as having funded their own trust. The two trusts must differ meaningfully in timing, assets, trustees, and terms.
- **Distributions.** Money distributed to the beneficiary spouse and deposited into a joint account is exposed again.

Qualified personal residence trust (QPRT)

A QPRT holds a residence. The owner keeps the right to live there for a fixed term of years, after which the home passes to children or a trust for them. The gift is valued at a discount because the children must wait. Higher interest rates enlarge that discount.

During the term, a creditor can reach only the owner's remaining right of occupancy, which has little market value. The remainder already belongs to the beneficiaries. After the term, the owner holds no interest and must pay fair market rent to stay, which moves still more wealth out of the estate.

The tradeoffs are real:

- If the grantor dies during the term, the home is pulled back into the taxable estate.
- The children take the parents' income tax basis and lose the step-up at death.
- The home generally cannot be refinanced easily once inside the trust.

> "For a California surgeon, [a domestic asset protection trust] is the most oversold product in the field."

- Since Proposition 19 took effect in 2021, the transfer to children at the end of the term will usually trigger property tax reassessment unless a child moves in as a primary residence, and even then the exclusion is capped.

For a long-held California home with a low assessed value, the Proposition 19 cost alone can outweigh the benefit. Run the numbers before signing.

Charitable remainder trust (CRT)

The donor transfers appreciated assets to a CRT. The trust sells them without immediate capital gains tax and pays the donor an income stream for life or a term of up to 20 years. What remains passes to charity. The donor receives a partial income tax deduction and spreads the gain over many years.

The principal in a CRT is irrevocably committed to charity, so no creditor of the donor can reach it. The exposed piece is the income stream. Because the donor retained it, California law lets a creditor reach each payment as it comes due. A CRT therefore converts a large, seizable, appreciated asset into a modest annual payment that is far less attractive to pursue.

CRTs fit appreciated securities and unencumbered real estate before a sale is negotiated. They are generally unsuitable for S corporation stock, professional corporation shares, and mortgaged property. Many families pair the CRT with life insurance in an irrevocable trust to replace what goes to charity.

Irrevocable life insurance trust (ILIT)

Because California gives life insurance cash value almost no exemption, a policy owned personally is an exposed asset. A policy owned by an ILIT is outside both the taxable estate and the reach of creditors, and the death benefit can stay in trust for the family.

Domestic asset protection trusts: a poor fit for Californians

About twenty states, including Nevada, South Dakota, Delaware, Alaska, and Wyoming, have statutes that allow a domestic asset protection trust (DAPT). This is a trust you fund, of which you remain a beneficiary, and which your creditors supposedly cannot reach after a short waiting period. For a resident of one of those states with assets there, a DAPT can work. For a California surgeon, it is the most oversold product in the field.

The weaknesses are structural:

- **California public policy.** California has no DAPT statute, and Probate Code section 15304 says the opposite. A California judge deciding a California creditor's claim against a California debtor is likely to apply California law and disregard the Nevada statute as contrary to the forum's strong public policy.
- **Full faith and credit.** A California judgment must be honored by the courts of every other state. The creditor can domesticate it in Nevada or sue the trustee directly. In *Toni 1 Trust v. Wacker* (2018), the Alaska Supreme Court held that Alaska could not reserve to its own court's exclusive jurisdiction over challenges to an Alaska DAPT.
- **The case law runs one way.** In *In re Huber* (2013), a bankruptcy court refused to apply Alaska law to an Alaska DAPT created by a Washington resident and set the trust aside. In *Kilker v. Stillman* (2012), a California appellate court upheld an order setting aside a California resident's transfers to a Nevada DAPT. In *Dahl v. Dahl* (2015), Utah's Supreme Court applied Utah law to a Nevada trust.
- **Bankruptcy.** Section 548(e) of the Bankruptcy Code gives a trustee ten years to unwind a transfer to a self-settled trust made with intent to hinder creditors. A creditor can force that forum with an involuntary petition.
- **In-state assets.** If the trust holds California real estate or an interest in a California practice, a California court has direct power over the asset regardless of where the trust is administered.

Practitioners have yet to point to a reported decision that upheld a DAPT for a resident of a non-DAPT state against a determined creditor. A DAPT may add friction and settlement leverage, and some advisers use one as a secondary layer for that reason. It should never be the core of a California surgeon's plan, and no one should pay for it believing it is proven.

Better alternatives reach a similar goal on firmer ground. A SLAT is a third-party trust and not self-settled. A "hybrid" trust is created for a spouse and descendants, with an independent party holding the power to add the grantor as a beneficiary later if needed. It starts as a third-party trust and stays outside section 15304 unless and until that power is used.

Offshore trusts: the strongest tool, with hard limits

A properly established offshore asset protection trust is the most formidable barrier available to a U.S. resident. It is also the most expensive ($20-35,000 to set up and $5-7,000 per year in maintenance fees) and the most misunderstood, and it is the tool most likely to put a client in front of an angry judge.

Why it is strong. A domestic trust fails because a U.S. court can order a U.S. trustee to turn over assets. An offshore trust places legal ownership with a licensed trustee in a jurisdiction such as the Cook Islands or Nevis, and that trustee does not answer to a California court. These jurisdictions built their statutes for this purpose:

> "The trust protects the assets. It does not protect the settlor, who still lives and practices in California."

- They do not recognize or enforce foreign judgments; the creditor must file a new case there.
- The limitations period for challenging a transfer is short, generally one to two years.
- The creditor must prove fraudulent intent to a standard approaching beyond a reasonable doubt.
- Contingency fees are restricted, and a creditor may have to post a bond to proceed.
- A duress clause directs the trustee to ignore any instruction the settlor gives under court compulsion.

Faced with those costs, most creditors settle for a fraction of the claim. That leverage is the real function of the trust.

Where it fails. The trust protects the assets. It does not protect the settlor, who still lives and practices in California.

- **Contempt.** A court that cannot reach the trustee can reach you. In *FTC v. Affordable Media* (1999), known as the Anderson case, the Ninth Circuit upheld the jailing of a couple who claimed they could not repatriate Cook Islands trust funds. The court held that an impossibility the debtor created is no defense. *In re Lawrence* in the Eleventh Circuit ended with a debtor incarcerated for years. The Ninth Circuit's law governs California.
- **Assets must be offshore.** A Cook Islands trust that owns a California rental, or an LLC holding one, protects nothing. A California court has direct power over California land. Offshore trusts suit liquid assets held in foreign accounts.
- **Timing rules still apply.** A transfer made after a claim arises is voidable here no matter what Cook Islands law says, and the transferor faces the consequences here.
- **Bankruptcy.** The ten-year look-back applies, and a debtor who will not repatriate assets may be denied a discharge.
- **No tax benefit and heavy reporting.** The trust is a grantor trust, and all income is taxed to the settlor. Forms 3520 and 3520-A, FBAR filings and Form 8938 are required every year. Penalties for missed filings can reach 35 percent of the amounts involved.
- **Cost and loss of control.** Expect a five-figure setup fee and several thousand dollars a year. If you keep real control, a court will find it. If you give up real control, you must be comfortable with a foreign trustee holding your savings.

Who should consider one. An offshore trust can be appropriate for a surgeon

with substantial liquid net worth who has already used insurance, exemptions, entities, and domestic trusts. It must be funded years before any claim, with a portion of assets that leaves the surgeon clearly solvent, and fully reported to the IRS. Anyone who offers one as a tax shelter, promises secrecy, or proposes it after a lawsuit has been threatened should be shown the door.

Fake liens and sham "equity stripping"

A recorded lien from an entity you control, securing a debt that does not exist, is not asset protection. It is a false public record, and it is the most dangerous scheme marketed to physicians and dentists.

The pitch is appealing. A Nevada or Wyoming company, quietly owned by the surgeon or run by the promoter, records a deed of trust against the surgeon's home or a UCC lien against practice receivables. A plaintiff's lawyer who searches title supposedly sees no equity and walks away.

It fails, and it fails badly:

- **It does not survive discovery.** In a judgment debtor examination, the surgeon must answer under oath who the lender is, when the money was advanced, and where the payments went. There are no bank records to support a loan that never happened. The choice at that point is to admit the sham or commit perjury.
- **A lien secures only real debt.** With no consideration behind it, the deed of trust is void, and a court will strike it.
- **It is a voidable transfer.** Granting a lien is a "transfer" under the statute, and a lien granted to an insider for no value carries nearly every badge of fraud.
- **It can be a felony.** Knowingly recording a false instrument violates Penal Code section 115. Asserting the lien in a bankruptcy case adds federal exposure for bankruptcy fraud.
- **It poisons everything else.** A judge who finds one sham document will look hard at the LLCs, the retirement plan, and the trusts, and legitimate planning may be swept aside with it.

> "A recorded lien from an entity you control, securing a debt that does not exist, is not asset protection."

- **It can put a dental license at risk.** A finding of fraud or dishonesty can lead to discipline by the Dental Board.

Genuine equity reduction is different. A real loan from an unrelated commercial lender, with funds advanced and then held in exempt or well-structured form, is legitimate. The test is simple: did real money move, at arm's length, and can you prove it?

What about a home equity line of credit? A HELOC is the version of equity stripping surgeons hear about most, and it deserves a realistic assessment.

- **An undrawn line protects nothing.** The recorded deed of trust shows the full credit limit and may discourage a casual title search. The lien secures only what has been borrowed, and the true balance comes out in discovery.
- **A drawn line does reduce equity.** It is real debt to an arm's-length lender and senior to a later judgment lien. Because the homestead exemption sits behind consensual liens, the two together can leave a creditor little to reach in the home.
- **The borrowed cash becomes the exposed asset.** Loan proceeds sitting in a brokerage account are as reachable as the equity was. Moving them into protected form is a separate transfer, judged under the same voidable transaction rules.
- **It cannot be a last-minute move.** Lenders can freeze or reduce a line when credit deteriorates, as many did in 2008. Drawing the line after a claim arises and moving the cash is a textbook badge of fraud.
- **It has a carrying cost.** The surgeon pays variable-rate interest, much of it non-deductible, on money that may earn less than it costs.

A HELOC opened well in advance is useful as emergency liquidity and as a modest deterrent. It is weak as a standalone strategy, and it is never a substitute for the layers described above.

What else experienced counsel will tell you

Layer the plan. No single device is sufficient. A sound plan stacks protections so a creditor must defeat each in turn: insurance first, then statutory exemptions, then entities that isolate risky assets, then irrevocable trusts, and only then, for the right client, an offshore component.

Do not protect everything. A plan that leaves the surgeon insolvent on paper is voidable on its face, and a judge will not accept that a successful surgeon owns nothing. Leave enough exposed to pay reasonably foreseeable claims and to support a credible settlement. The goal is to protect a core nest egg, not to become judgment-proof.

Reduce the source of risk. Structure is the second line of defense. The first is fewer claims:

- Rigorous informed consent and documentation, especially for third molars, implants near the nerve, and orthognathic cases.
- Anesthesia protocols, monitoring, emergency drills, and staffing that meet or exceed Dental Board permit requirements.
- An employee handbook, wage-and-hour compliance, and EPLI coverage.
- HIPAA security practices and cyber coverage.

Control vehicle liability. In California, the owner of a vehicle is liable, within statutory limits, for a permissive driver's negligence, and a parent who signs a minor's license application is liable too. Title each car in the name of its primary driver. Do not title vehicles in the practice or in an LLC that holds other assets.

Limit personal guarantees. Negotiate guarantees on leases and loans. Ask for a cap, a burn-off after a period of timely payment, and several liability among partners in place of joint liability.

Put partner arrangements in writing. A buy-sell agreement, clear indemnities, and separate coverage for each surgeon reduce the chance that one partner's problem becomes everyone's.

Protect what you inherit and what you leave. Ask your parents to leave your inheritance in a discretionary trust for you and not outright. A trust funded by someone else is the strongest protection California law allows, and it costs you nothing. Do the same for your own children with lifetime trusts, which protect against their creditors and divorces.

Coordinate before a practice sale. A sale to a partner or a dental support organization converts an illiquid practice into exposed cash. Charitable trusts, retirement plan funding, and trust transfers must be arranged before a letter of intent is signed.

Maintain the plan. Hold annual LLC meetings, keep separate accounts, pay rent under written leases, file every tax and information return, and review the plan every two or three years or after a move, marriage, divorce, sale, or change in the law.

> "The goal is to protect a core nest egg, not to become judgment-proof."

Choose advisers carefully. Use a California-licensed attorney who practices in both estate planning and creditor rights, working with your CPA and insurance broker. Walk away from anyone who promises a bulletproof result, sells a one-size package at a seminar, emphasizes secrecy, offers tax savings from an offshore structure, or is willing to start after you have been served.

Conclusion

Asset protection is to a surgeon's finances what a preoperative workup is to a surgical case: it is done before the incision, it is tailored to the patient, and it is useless once the complication has occurred. The surgeon who acts while solvent and claim-free has lawful, durable options at every level of wealth. The surgeon who waits for the demand letter has almost none. ■

This article is for general educational purposes and is not legal, tax, or financial advice. Asset protection law is fact-specific and changes frequently. Statutory figures and case references should be confirmed with current sources. Readers should consult a California-licensed attorney and tax adviser before acting on any strategy discussed here.

VOLUME 28, Nº 2 · FALL 2026

CYBERSECURITY



The New Face of Cybercrime: How Hackers Are Targeting Oral Surgery Practices in 2026

No organization or security tool can guarantee immunity to cyberattacks, but you can make your practice significantly harder to compromise, faster to detect threats, and better prepared to recover if something goes wrong.

AUTHOR



Paul Murphy
Chief Growth Officer,
Black Talon Security, LLC

Artificial intelligence helps cybercriminals launch faster, smarter, and more convincing attacks. Here's what every oral and maxillofacial surgery practice needs to know, and why protecting your practice may be easier than you think.

For years, many oral and maxillofacial surgery (OMS) practices operated under a dangerous assumption: cybercriminals primarily target large hospitals, corporations, and healthcare systems and that private practice owners were not a target for criminal hackers.

In 2026, that assumption couldn't be further from the truth.

Today's cybercriminals are increasingly targeting smaller healthcare organizations, including oral surgery practices. These practices possess something hackers desperately want: valuable patient information, financial data, and technology systems that are essential to daily operations. The number of ransomware attacks launched against private practice providers is much higher than those launched against hospital groups.

But something significant has changed in 2026. Artificial intelligence (AI) is giving cybercriminals the ability to launch more sophisticated attacks, identify weaknesses faster, and deceive employees more convincingly than ever before. The good news? Understanding how these attacks work and making a few strategic improvements to your cybersecurity defenses can dramatically reduce your practice's exposure.

AI Is Making Cybercriminals More Convincing

One of the most concerning developments in cybersecurity is how criminals are using AI to manipulate people. Historically, phishing emails were often easy to recognize. Poor grammar, suspicious links, and unusual requests frequently exposed fraudulent messages. Today, AI can eliminate many of those warning signs.

Imagine your scheduling coordinator receives an email that appears to come from a referring dental practice. The message references a patient consultation, uses familiar terminology, and requests that the coordinator open an attached referral document.

Everything looks legitimate. Unfortunately, the message was created by a cybercriminal using AI to impersonate a trusted referral partner.

With information gathered from websites, social media, and publicly available business records, attackers can generate highly personalized emails in seconds. AI can also help criminals impersonate voices, potentially allowing someone to call your front desk pretending to be a peer, office manager, or IT technician.

The objective is simple: convince an employee to disclose credentials, authorize fraudulent payment, or provide access to practice systems. The danger is no longer just suspicious emails. It's communications that look and sound remarkably legitimate.

Every oral surgery practice relies on technology: practice management software, imaging systems, servers, firewalls, cloud applications, and remote access tools.

These systems periodically develop security vulnerabilities that require updates or other protective measures. In the past, identifying and exploiting these weaknesses often required considerable technical expertise and time. AI is changing that equation.

Microsoft's 2026 Digital Defense Report describes how AI is being applied to vulnerability discovery, reconnaissance, and exploit development. In some cases, attackers can weaponize newly discovered vulnerabilities in less than 24 hours.

"The danger is no longer just suspicious emails. It's communications that look and sound remarkably legitimate."

Consider what this means for oral surgery practices. A vulnerability is discovered in a commonly used remote access application. Before the practice's IT provider has applied the necessary security update, automated attackers may already be searching the internet for exposed systems. If the practice is vulnerable, criminals may gain unauthorized access without anyone clicking a malicious email. This is why relying exclusively on occasional vulnerability scans or annual cybersecurity assessments is becoming increasingly risky and antiquated approach to security.

Hackers Are Exploiting the Tools Practices Already Trust

Another troubling trend involves cybercriminals abusing legitimate software.

Remote-support applications such as ScreenConnect, TeamViewer, and other remote management tools are widely used by IT professionals to maintain computer systems.

Unfortunately, these same tools can be exploited or misused by attackers. A criminal might convince an employee to install remote support software by pretending to be an IT technician. Alternatively, attackers may exploit a vulnerability in an existing remote access system.

Once connected, they may attempt to steal passwords, access patient records, or move between computers. For oral surgery practices, the consequences can be extremely disruptive. Imagine arriving Monday morning to discover that your imaging systems are inaccessible, patient schedules are unavailable, and clinical records cannot be retrieved. Procedures may need to be postponed, employees may be unable to perform their jobs, and patients may lose confidence in the practice. Even when criminals don't encrypt files, they may steal sensitive information and threaten to publish it unless a ransom is paid.

Why Oral Surgery Practices Are Attractive Targets

Oral surgery practices have several characteristics that make them appealing to cybercriminals. They store sensitive patient information, communicate frequently with referring dental offices, process significant financial transactions, and depend heavily on technology for patient care. A high percentage of oral surgery practices also have limited internal security measures in place and are under tremendous pressure to restore operations quickly in the event of an attack.

The Good News: A Few Changes Can Make a Big Difference

Despite these developments, oral surgery practices should not feel helpless.

In fact, many successful cyberattacks exploit weaknesses that can be significantly reduced through practical, affordable improvements.

Practices should focus on five priorities:

1. Implement stronger email security. Use advanced email protection capable of identifying impersonation, malicious links, suspicious

INSIDE AN AI-POWERED ATTACK

How it unfolds, and how fast

1 Research
Attackers gather details from websites, social media and public business records.

2 Impersonate
AI writes a personalized email, or mimics a voice, posing as a referring office, peer or IT technician.

3 Get in
An employee shares a password, approves a payment or installs remote-support software.

4 Disrupt
Criminals steal records, lock up imaging and schedules, and demand a ransom.

< 24 hours

In some cases, attackers can weaponize newly discovered vulnerabilities in less than 24 hours.

attachments, and potential account takeovers.

2. Continuously identify and remediate vulnerabilities. Move beyond occasional scans toward continuous threat exposure management (CTEM), prioritizing weaknesses that attackers could realistically exploit. There are multiple inexpensive tools available today that provide this service.
3. Strengthen employee awareness. Incorporate short, frequent training that teaches employees to recognize AI generated phishing, fraudulent requests, and suspicious remote support activity. Verify sensitive requests through trusted communication channels.
4. Secure access to critical systems. Implement phishing resistant multifactor authentication where possible, restrict unnecessary remote access, and use advanced endpoint protection with active security monitoring.
5. Prepare for rapid recovery. Maintain protected, tested backups and a practical incident response plan so the practice can restore operations quickly if an attack occurs.

Cyber Resilience is Within Reach

The cybersecurity landscape of 2026 is undoubtedly more complex than it was just a few years ago. AI helps criminals work faster, impersonate trusted individuals, and exploit technical weaknesses with greater efficiency. But the same technological advances are also improving cybersecurity defenses. Modern security solutions can continuously monitor threats, identify suspicious behavior, prioritize vulnerabilities, and address issues before minor weaknesses become major incidents.

The goal isn't to make oral surgery practices completely immune to cyberattacks. No organization or security tool can guarantee that. The goal is to make your practice significantly harder to compromise, faster to detect threats, and better prepared to recover if something goes wrong.

By taking a proactive approach and making a handful of meaningful security improvements, oral surgery practices can protect their patients, preserve operational continuity, and confidently embrace new technology. Because ultimately, cybersecurity shouldn't be about living in fear of the next attack. It should be about having the confidence that your practice is prepared for it. ■

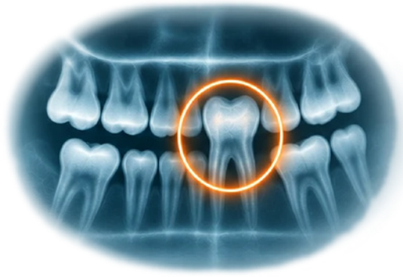

Wrong-Tooth Extraction After Conflicting Referral Documentation

AUTHOR

Nicole Franklin, MS, CPHRM
Patient Safety and Risk Manager II,
The Doctors Company

The Doctors Company
TDCGROUP

Wrong-site dental procedures are preventable events that may cause permanent loss of healthy dentition, as well as additional restorative treatment, emotional distress, and loss of patient trust. Further, wrong-site events create liability exposure for practitioners and practices. Using an evidence-based taxonomy,[1] The Doctors Company has analyzed malpractice allegations against oral and maxillofacial surgeons to help practitioners and their teams identify opportunities to proactively mitigate risks.

Case Study

An oral and maxillofacial surgeon (OMS) allegedly extracted the wrong permanent molar after relying on an incorrect referral note and failing to reconcile the identified tooth with the diagnostic imaging and clinical findings.

Background

A patient was evaluated by a general dentist for a longstanding intermittent toothache. The dentist's record contained two conflicting notes from the same encounter. One note identified the symptomatic tooth as the upper right first molar, while the other identified the upper left first molar.

Radiographic and cone-beam computed tomography imaging demonstrated disease involving the upper right molar. The general dentist diagnosed an infection, recommended extraction of the left upper molar, and referred the patient to an OMS.

At the OMS practice, the patient signed a consent form authorizing extraction of the upper left molar. The OMS placed the patient under anesthesia and extracted the upper left molar. Upon awakening, the patient recognized that the painful upper right molar remained in place. The OMS contacted the referring dental office and was told that its records identified the upper left molar. At that time, the OMS reviewed the radiograph transmitted with the referral and identified disease in the upper right molar.

The patient later underwent extraction of the correct tooth by another OMS. The patient related experiencing pain and irritation at the site of the wrong extraction, in addition to the necessity for additional treatment, including a sinus lift and dental implant.

During discovery, the patient reported that their encounter with the OMS felt rushed; the patient did not understand the dental numbering system, and the OMS did not ask them to indicate the location of their symptoms. The OMS said that it was their usual practice to perform an oral examination; however, there was no documentation in the dental record of examination or clinical findings supporting extraction of the upper left molar. The operative note indicated that the upper left molar had been removed in accordance with the referral.

BY THE NUMBERS

What OMS malpractice claims involve

229

malpractice allegations against OMS practices, closed 2010–2025



Source: The Doctors Company. Bars show each figure as a share of the 229 total; wrong-tooth cases are part of improper surgery performance.

A defense expert could not support the OMS's care. The expert criticized the failure to closely review and reconcile the imaging with the written referral, the absence of a documented oral examination, and the consent process, which identified the extraction site by tooth number without explaining it in terms the patient could readily understand. The expert also concluded that the removed tooth had no documented indication for extraction. The referring dentist and OMS both settled the claim.

Commentary

The Doctors Company reviewed 229 allegations of medical malpractice against OMS practices, claims that closed between 2010 and 2025. Fifty-seven claims involved improper surgery performance, including 35 wrong-tooth or wrong-teeth procedures. Communication and documentation issues were also common, appearing in 33 percent and 20 percent, respectively, of all claims studied.

This case demonstrates how an initial documentation error can pass through several stages of care when each subsequent professional assumes that the information received is correct. A referral is an important source of information, but it should not substitute for the treating surgeon's own evaluation of the patient, symptoms, oral findings, and imaging. The absence of a documented examination by the OMS weakened the defense.

Patient Safety Considerations

Use a standardized preprocedure verification process for every surgical procedure. Reconcile the referral information with clinical examination findings, additional diagnostic imaging if needed, and the patient's treatment plan, consent form, and operative schedule. Any inconsistency should result in a hard stop until it is resolved and documented. A deliberate, team-based verification process provides multiple opportunities to identify and correct discrepancies before an irreversible procedure occurs.

Immediately before any procedure, conduct an active surgical time-out with all participants present. The surgeon should verbally confirm the correct patient, correct procedure, and correct site as confirmed by the patient or guardian, review of radiology images, and the consent form. The time-out should not be treated as a routine checkbox or completed while staff members are distracted.

Establish a process for handling incomplete, conflicting, or amended referrals. Staff members should not independently infer which document is correct. Clarification should come directly from the referring dentist and be documented in the record. Revised referrals and images should be clearly labeled, dated, and incorporated into the operative plan.

Wrong-tooth extraction is rarely the result of a single mistake. In this case, conflicting documentation, assumptions about a referral, inadequate examination, limited patient understanding, and an ineffective preoperative verification process combined to allow the error to reach the patient. ■

The guidelines suggested here are not rules, do not constitute legal advice, and do not ensure a successful outcome. The ultimate decision regarding the appropriateness of any treatment must be made by each healthcare provider considering the circumstances of the individual situation and in accordance with the laws of the jurisdiction in which the care is rendered.

©2026 J03465B 8/26

[1] *Copyrighted by and used with permission of Candello, a division of The Risk Management Foundation of the Harvard Medical Institutions Incorporated, all rights reserved.*

Continuing Education & Events

Upcoming Live Events

SATURDAY, JANUARY 16, 2027

2027 January Meeting Webinar

9:00 am – 3:15 pm PT
Online
Registration open until January 15

APRIL 24–25, 2027

27th Annual Meeting

Napa Valley Marriott Hotel & Spa, Napa
9 units of anesthesia CE
Optional add-on AAOMS OBEAM course

See all events and register at calaoms.org/events

On-Demand Courses

Earn CE on your own schedule. A separate email address is required for each registrant.

Safeguarding the Modern Practice, Parts 1–3 (Black Talon Security)
1 CE unit each • $60 each

California Dental Practice Act
2 CE units (mandatory for license renewal) • $50

California Infection Control
2 CE units (mandatory for license renewal) • $50

California DPA and Infection Control Bundle
Both courses, 4 CE units • $75

A Safe Approach to Opioids in Dental Practice
2 CE units • $60

Managing Stress in the OMS Environment With Confidence
1 CE unit • Free for members

calaoms.org/store/on-demand

Office Managers Forum

On demand • Free for members and staff

PART 1 • 2 CE

The Wrong Hire Can Bite: How to Protect Your Practice from Problem Employees

2026 Compliance Roundup: Wages, Leave, AI, and What Every Dental Office Manager Needs to Know

PART 2 • 1 CE

Preventing Social Engineering – The Exploitation of Human Trust

PART 3 • 1.5 CE

The Online Ecosystem: How AI Is Changing the Way Patients Choose Your Oral Surgery Practice

calaoms.org/store/on-demand

VOLUME 28, Nº 2 · FALL 2026

CLASSIFIEDS

Classified Ads

Current listings from calaoms.org/classified-ads as of November 2026. Please contact each listing directly; see the website for the latest.

ASSOCIATE AND PARTNERSHIP POSITIONS

Orange County: OMS practice for associateship/sale. Great location Orange County. Large referral base. No HMOs; dentoalveolar and implant surgery. Fully equipped O.R., no need to take cases to hospital, anesthesiologist on duty, no E.R. calls. Experienced and well-trained staff. The seller is retiring and motivated. Please send resume to: scalpel_4me@yahoo.com

Rancho Mirage: Mirage Center for Oral & Maxillofacial is a well-established, patient-centered OMS practice located in Rancho Mirage, California. We are excited to welcome a talented Associate Oral Surgeon to our collective. Rancho Mirage is one of those rare locations for an oral surgeon where clinical demand, patient ability to pay, and lifestyle all line up! This is a unique opportunity that offers a clear path to practice ownership and a comprehensive benefits package.

Why Rancho Mirage?

Rancho Mirage, California, sits in the Coachella Valley and offers abundant sunshine, mild winters, year-round golf, tennis and is within driving distance to big-city culture and beach weekends in Los Angeles, Orange County and San Diego.

Why Join Us?

Modern, Established Practice: Our state-of-the-art facility is fully equipped with CBCT, lasers, 3Dprinter, digital workflow, and boasts a strong referral network.

Supportive Team Environment: Join a collaborative team of experienced professionals dedicated to excellence in patient care and continuing education.

Equity & Ownership Opportunity: We're offering a clear pathway to equity and future practice ownership. Ideal for an associate seeking to build a stable, long-term career with shared success.

What We're Looking For:

- Board-Certified or Board-Eligible Oral Surgeon
- DMD/DDS from an accredited U.S. dental school and Certificate in Oral Surgery
- Active California dental license (or ability to obtain)
- Integrity, communication and strong interpersonal skills
- Commitment to excellence in patient care and clinical outcomes
- Interest in long-term partnership and leadership within the practice

Please send your CV to nlachance@MosaicDentalCollective.com

Roseville: Immediate full-time oral surgeon needed to join our team in Roseville, CA. Practices a full scope of oral and maxillofacial surgery with expertise ranging from corrective jaw surgery to wisdom teeth extraction to teeth-in-an-hour/ Dental Implants. Diagnoses and treats facial pain, facial injuries and TMJ disorders, and performs a full range of dental implant and bone grafting procedures.

Galleria Oral & Maxillofacial Surgery
Roseville, CA

Please contact - Dr. Antipov

Phone (call or text): 916-769-8900

Email: info@galleriaoms.com

Sacramento: Busy two location practice seeking full-time OMS to join our team. The practice is doctor owned and has been established in the Sacramento area for over 30 years with a new location opening later this fall. Scope is traditional office based surgery with a high volume of bone grafting, implants, 3rd molars, and full-arch implant cases. No hospital call. Offices are equipped with CBCT, intraoral scanners, and AI powered EMR. Excellent opportunity for a new or experienced surgeon. You will have a full schedule on day one. Please send CV and letter of interest/inquires to: dalealto@gmail.com

San Diego: Rare opportunity to join a well-established and respected oral surgery practice located in central San Diego. One of the most successful and busy practices in the city at a tender age of 30 and still going STRONG. Very active Seattle study club supporter for over 25 years with 40 members. Scope of practice includes all dentoalveolar surgery, implants, bone grafting, PRF/PRP active use, orthognathic and TMJ surgery, sleep apnea treatment with MRD and bi-maxillary advancement and facial trauma. In house OR capable of supporting single jaw orthognathic/TMJ surgeries. Active hospital practice for more complex cases.

We are looking for a California licensed board certified/eligible surgeon with active skills in orthognathic/TMJ/Trauma surgery comfortable with outpatient anesthesia and dentoalveolar surgery that is interested in learning, growing, collaborating with a continuing interest to develop professionally as well as personally. Comfort with public speaking is a big plus. Outgoing personality with excellent patient care skills and engaging chairside/bedside manner are mandatory. Interested parties, please contact via email to info@mvoms.com, or office phone at 619-298-2200 x107 and ask for May, Director of Operations.

San Francisco - Union Square: Excellent private practice is looking for a full or part time oral surgeon to join our wonderful and professional team. Please send CV and letter of interest / inquiries to: sfomfsjob@gmail.com

OMS POSITIONS

La Jolla: Scripps Center for Dental Care is seeking a board certified Oral Surgeon with minimum 5 years of post training clinical experience. We are looking for a long-term commitment of 1-2 days per week and someone with excellent interpersonal and team skills. Our practice is a progressive, high quality, multi-specialty, patient centered dental office located on Scripps Memorial Hospital campus. Our team consists of 8 doctors, 4 hygienists, and 16 additional supporting team members all committed to exceptional patient care in a true interdisciplinary approach in one location. The office location in close proximity to research, medical, and professional environments combine for a very strong and reliable patient base. Our team is expertly trained and the office is outfitted with modern equipment and systems including optical impressioning, 2D/3D digital radiography, electric hand pieces, hard/soft tissue lasers, microscopes, intra-oral cameras, 3D printing, etc. We do not participate in any capitation or managed care programs. Our growth is sustained primarily by clinician and patient referrals. For additional information, please visit: www.scrippsdentalcare.com. Send bio, resume and photo to: admin@scrippsdentalcare.com

Kids Care Dental & Orthodontics is hiring talented oral and maxillofacial surgeons to join our team. KCD&O is a doctor-led and patient-centered pediatric practice that offers multi-disciplinary services across pediatric dentistry, orthodontics and oral surgery. We are one of the largest pediatric dental groups in the state and currently have 25 practices throughout Sacramento, the San Francisco Bay Area, and the Central Valley of California. You will work with an experienced practice management staff and have the opportunity to collaborate and share insight with our orthodontists and pediatric dentists. The scope of practice includes routine dentoalveolar surgery for children and young adults. We accept either fee-for-service or PPO's and our surgeons enjoy competitive compensation with high earning potential, and group benefits including health, dental, vision, life/AD&D and professional liability insurance, and a 401(k) savings plan. We are currently looking for skilled oral surgeons to join our team at our northern California locations as we are growing. Requirements are a CA license and a GA permit. If you are interested in exploring an opportunity with Kids Care Dental & Orthodontics, please contact us and send your CV to drtalent@kidscaredental.com

San Diego - Part Time Oral Surgeon Opportunity: Well-established, busy, privately owned, non-DSO pediatric dental practice in San Diego is seeking an Oral and Maxillofacial Surgeon interested in providing in-office surgical services on a part-time basis.

We have a large existing patient base and steady internal demand for oral surgery, particularly teenagers and young adults requiring third-molar extractions, as well as younger patients requiring extractions and other appropriate surgical procedures. Our goal is to allow our patients and families to receive these services in the familiar practice they already know and trust rather than being referred elsewhere.

We envision starting approximately one day per week, with Fridays readily available, but scheduling is flexible. There is also opportunity to add additional days as patient demand supports it.

The practice provides an established patient flow, clinical space, experienced staff, and administrative support for scheduling and patient coordination. There is no expectation for the surgeon to independently develop a referral base. We are looking for an OMS who is clinically excellent, personable, and enjoys working with children, adolescents, young adults, and their families. The specific arrangement, including scheduling, staffing, supplies, and compensation, can be developed collaboratively with the right surgeon. Excellent opportunity for an OMS looking to add a productive recurring surgical day to an existing schedule with the potential for growth.

Interested candidates: Please email SDOMSdoc@gmail.com for additional information and a confidential discussion

San Francisco: Established, high-quality private oral surgery practice in San Francisco seeks a full-time associate, preferably as an independent contractor. We offer competitive compensation, modern facilities, a strong referral network, and direct mentorship from highly experienced oral and maxillofacial surgeons. The ideal candidate is board-certified or board-eligible, patient-centered, and clinically skilled in dentoalveolar surgery, implants, anesthesia, and office-based procedures. New graduates and experienced surgeons are encouraged to apply. Confidential inquiries are welcome. Please contact sfomsjobs@gmail.com

San Francisco - Union Square: Excellent private practice is looking for a full or part time oral surgeon to join our wonderful and professional team. Please send CV and letter of interest / inquiries to: sfomfsjob@gmail.com

DOCTORS SEEKING POSITIONS

No Listings at This Time

FACULTY POSITIONS

No Listings At This Time

PRACTICES FOR SALE

East Bay: Incredibly well respected and a fixture in the East Bay Oral Surgery community, this practice has been established for over 25 years and seeks an equally talented but younger oral surgeon to bring this practice to its ultimate potential. This fully equipped practice in approximately 2500 sq. ft. features two treatment rooms (room for a third) and three consultation rooms and an opportunity to expand. Long established with systems and processes in place for high volume of production and patients, gross revenues are approaching $3M per year. The owner is retiring but willing to stay on one or two years to ensure a smooth transition. The office is ideally located along 580 and sees patients from Dublin, San Ramon, Castro Valley, Pleasanton and Livermore—among others. Priced below market value, attract newer graduates or seasoned veterans with the opportunity to own a prestigious, well-known practice and build a new legacy. For more information, please send a cover letter and current CV to smolinelli@ddsmatch.com or gina@ddsmatch.com or call 650-347-5346.

Bakersfield: Long established OMS practice located in a new office in the heart of town. This busy practice is perfectly located in the middle of Bakersfield with all major highways intersecting within a few blocks from the office. Within 10 minutes of both Mercy and Adventist Health hospitals, the office is also surrounded by many dental offices for referrals. I am currently doing 7-8 surgeries a day, and there is an extra room ready for a surgical suited making it easy to produce more surgeries a day if needed. The community is growing quickly, so you can't go wrong with this practice. Call 661-835-7389 or email genehughesdds.oralsurgery@gmail.com

Chico: Established | High-Producing | Real Estate Available. Ideal opportunity for oral surgeon seeking ownership with immediate cash flow. Exceptional opportunity to acquire a 35-year legacy Oral & Maxillofacial Surgery practice with deep community roots and a long-standing referral network. This highly profitable practice collects over $2.2M annually on a 3.5 day work week and is supported by a tenured, experienced team and state-of-the-art clinical technology. Established 3,000 sqft freestanding building; 3 fully equipped operatories 2 consult rooms; CBCT; Intraoral Scanner; Dentrix Practice Management Software; Modern clinical workflow and technology infrastructure; Real estate available for purchase. Interested parties should call (530) 321-7731 or email tbeltramo@gmail.com.

Los Angeles: "Turnkey, high-tech full scope oral and maxillofacial surgery practice in the LA suburbs with proximity to downtown LA, Hollywood, Burbank Studios, the westside, beaches, and Beverly Hills. Full scope practice offering Dentoalveolar, implants, full arch reconstruction, Zygoma implants, Pathology, reconstruction, orthognathic surgery, TMJ surgery, facial trauma and facial cosmetic surgery; IO Scanner, CBCT , 3D photography and 3D printer to facilitate digital workflows, anesthesia machine, and OR table set up for full-arch, orthognathic, TMJ, facial trauma, and cosmetic surgery cases. Affiliated with an OMS residency program. Stellar reputation with 40 years of goodwill and the only oral surgery practice in the zip code. Located on the first floor of a three-story building primarily occupied by dental offices, directly across the street from a community hospital with strong affiliation to facilitate hospital OMS cases and emergencies. 1,650 sq ft office with private parking and back-office access. Includes three operatories plus an OR suite ready for accreditation as an office-based

surgery center, recovery room,oxygen, nitrous, and vacuum setup in all rooms. Modern reception and waiting room, private doctor's office, business office, staff room, sterilization room, and bathroom. Gross collections averaging $1.45M over the last three years. Seller motivated due to moving out of the area. Rare opportunity in the LA area. email laoms2025@gmail.com for confidential information".

Orange County: OMS practice for associateship/sale. Great location Orange County. Large referral base. No HMOs; dentoalveolar and implant surgery. Fully equipped O.R., no need to take cases to hospital, anesthesiologist on duty, no E.R. calls. Experienced and well-trained staff. The seller is retiring and motivated. Please send resume to: scalpel_4me@yahoo.com

Sonoma, CA: Practice for sale, FACILITY ONLY. Turnkey operation. Great opportunity. Dr. Retiring. Please respond to (510)409-0742 or nfantovrn@aol.com for inquires.

Santa Barbara: Central coast 40+ years established OMS practice. Office located near a level 1 trauma hospital. Call 805-692-8500 or email drwelsh.oms@gmail.com with any questions. Price $800,000

Silicon Valley: Oral Surgery Practice seeks buyer to continue a decades long tradition of providing quality OMS services to a traditional referral base in San Jose, Los Gatos and Saratoga. Interested prospects can send a CV to molinelli@aol.com or call 650-347-5346.

OFFICE SPACE FOR SALE OR LEASE

West Hollywood Area Fully Equipped General Dental office in West Hollywood area is offering full/part time sublease.

4 operatories, days and hours are flexible. free parking on the plaza available.

Has elevator and handicap accessibility.

Terms are negotiable. Please call 310-435-7146, or email smile@citydentalonline.com

LOOKING TO PURCHASE

Southern California: Southern California: I am a practicing oral and maxillofacial surgeon in LA. I am looking for an OMS practice for purchase with or without transition. Los Angeles preferred. Please email me at alexleeomfs@gmail.com.

EQUIPMENT FOR SALE

No Listings at This Time

BACK OFFICE STAFF

No Listings at This Time

FRONT OFFICE STAFF

No Listings at This Time

California CCF Volunteers CareForce™

OUR IMPACT

Throughout my restorative service I felt safe and comfortable at the hands of two budding doctors who displayed great compassion."
~ Dental Patient ~

5,528 Patients Received Dental, Vision, and/or Medical Services
1,475 Professional and Community Volunteers
$1.7 Million in Healthcare Services Delivered

1,397 Dental Patients
- 1,262 Dental Exams
- 3,223 X-Rays
- 961 Extractions
- 648 Fillings
- 152 Dentures, Stayplates, Retainers and Mouth Guards
- 16 Crowns
- 6 Root Canals
- 722 Cleanings



MARK YOUR CALENDAR



Coachella Valley
February 26-February 28, 2027
Empire Polo Grounds - Indio, CA



Placer Veterans Stand Down
May 4-5, 2027
@theGrounds - Roseville, CA

CONNECT WITH US

"I wish all service providers were as thorough and thoughtful. Thank you all for your hard work!"
~ Dental Patient ~





Every smile restored, every pain alleviated, and every vision corrected is a testament to the incredible impact of California CareForce. Join us in Caring for California, one community at a time.

VOLUNTEER YOUR TALENTS & TIME: *Come join a clinic as a general volunteer or a healthcare professional. SCAN to sign up!*

LEAVE A LEGACY: *Include California CareForce in your estate planning today and make a difference tomorrow.*

DONATE TO THE CAUSE: *It's easy to make a significant impact with a donation. SCAN to make your gift!*

FOLLOW US: *Follow us on Facebook, Instagram, and LinkedIn.*



OMSNIC MEMBER
Dr. Brian Woo
UCSF School of Dentistry
Fresno, CA

OMSNIC is Your Company

OMSNIC offers OMS-exclusive medical professional liability protection and every insured is an owner of the company.

With the OMSCap™ preferred stock plan, OMS share in the company's success while benefiting from customized coverage, exclusive risk management education, and strong defense support if a claim arises. Rated A (Excellent) by AM Best – because your practice deserves excellence.

ASA OMS ENDORSED

800-522-6670

OMSNIC
DEFENDING THE SPECIALTY®

Learn more at **omsnic.com**